



PATIENT

Oscar Poles

PRESENTING CLINICAL SIGNS

Started coughing about 1 week ago and has gotten progressively worse. Owner thought was kennel cough as was exposed to a dog that had it. Has a heart murmur as well

SPECIES

Canine

RADIOGRAPHIC STUDY OF THE THORAX

Right/left lateral and dorsoventral views of the thorax totaling 3 images available for review.

BREED

Schnauzer Mix

RADIOGRAPHIC FINDINGS

The lungs are deeply inflated. The ribcage is expanded.

Severe left sided cardiomegaly is noted with a vertebral heart score of 13.5, loss of the caudal cardiac waist, marked left atrial tenting with splitting of the mainstem bronchi, and a perihilar accentuated alveolar pattern. The trachea is elevated. The pulmonary vasculature is dilated.

SEX

MN

Occasional age related incidental pulmonary osteomas are seen.

Course and width of the trachea are considered within normal limits.

AGE

13 Years

There appears to be mild generalized hepatomegaly with slightly rounded liver margins.

RADIOGRAPHIC DIAGNOSIS

- Severe left sided cardiomegaly with radiographic evidence of left sided congestive cardiac failure.
- Hepatomegaly.

INTERPRETED BY

Nele Eley, DVM
Dr. med. Vet. DipECVCI

INTERPRETATION OF THE FINDINGS & FURTHER RECOMMENDATIONS

The radiographic study reveals cardiogenic pulmonary edema and severe left sided cardiomegaly. Consider the presence of chronic mitral valve regurgitation with congestive heart failure a high potential. Degenerative mitral valve endocardiosis is one of the most common underlying causes. The use of diuretics appears to be indicated based on the radiographic findings. Consider a full cardiac echo for a more detailed staging.

HOSPITAL NAME

Chappelle Veterinary
Clinic

REFERRING VET

Bassam Abdelmelak

Differential diagnosis for the hepatomegaly includes metabolic/endocrine and degenerative hepatopathy. Diffuse inflammatory/infectious infiltrates are less likely.

INVOICE

52315

DATE

6-4-22



PATIENT

Oscar Poles

SPECIES

Canine

BREED

Schnauzer Mix

SEX

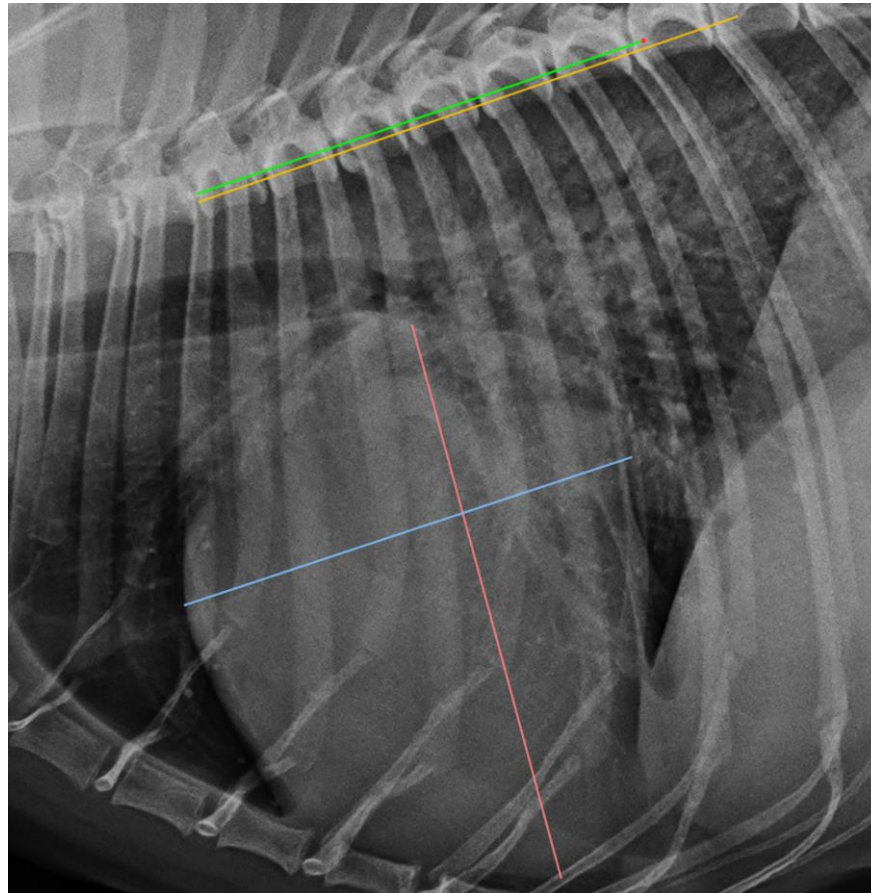
MN

AGE

13 Years

INTERPRETED BY

Nele Eley, DVM
Dr. med. Vet. DipECVDI



HOSPITAL NAME

Chappelle Veterinary
Clinic

REFERRING VET

Bassam Abdelmelak

INVOICE

52315

DATE

6-4-22

The information and recommendations provided are based on the images presented by the referring veterinarian/sonographer. No evaluation can be communicated regarding pathology that was not visible in the image/video clips provided.

Thank you for this referral. If the clinical or image interpretation does not parallel your findings or if I can be of any further assistance please contact me.

Nele Eley, DVM, Dr. med. vet., DipECVDI
European Specialist in Veterinary Diagnostic Imaging, Cert. Radiology,
Senior lecturer University of Giessen, Germany, Veterinary Faculty, Department of Radiology
Nele.Eley@sonopath.com