

**PATIENT**

Karma Bolger

PRESENTING CLINICAL SIGNS

History of grade 4-5 heart murmur, chronic coughing on and off. He is on Flovent puffer for possible asthma or allergy. Based on cardiologist, he is not on any heart medication. Please find attached the echocardiograph from Guelph.

SPECIES

Feline

RADIOGRAPHIC STUDY OF THE THORAX

Right/left lateral and dorsoventral views of the thorax totaling 4 images are available for review.

BREED

Siamese

RADIOGRAPHIC FINDINGS

Severe generalized cardiomegaly with severe atrial enlargement is seen. Basico-apical enlargement of the cardiac silhouette causes dorsal deviation of the trachea. The vertebral heart score is 11.

SEX

Male

The lungs are deeply inflated. The ribcage is expanded. The lumbodiaphragmatic angles are wide and the tips of the cranial lung lobes extend beyond the limits of the first rib pair.

A moderate generalized vascular lung pattern with a patchy interstitial infiltrate accentuating the perihilar and caudoventral lung is noted.

AGE

12 Years

Moderate spondylosis deformans is seen at T4/5.

INTERPRETED BY

Nele Eley, DVM
Dr. med. Vet. DipECVDI

RADIOGRAPHIC DIAGNOSIS

- Left sided congestive cardiac failure
- Moderate to severe cardiomegaly with atrial enlargement.
- Vascular lung pattern and cardiogenic pulmonary edema.
- Pulmonary hyperinflation

HOSPITAL NAME

Truscott Animal
Hospital

INTERPRETATION OF THE FINDINGS & FURTHER RECOMMENDATIONS

The radiographic findings are compatible with ongoing left sided congestive cardiac failure with cardiogenic pulmonary edema. The patient is suffering from chronic left/right shunting with atrial and ventricular septum defects and the radiographic findings strongly suggest presence of pulmonary volume overload with cardiogenic pulmonary edema. The use of diuretics appears to be indicated. The medication should be adjusted in agreement with the cardiologist in this case.

REFERRING VET

Dr. Medhat Meawad

INVOICE

59079

DATE

6-27-23



PATIENT

Karma Bolger

SPECIES

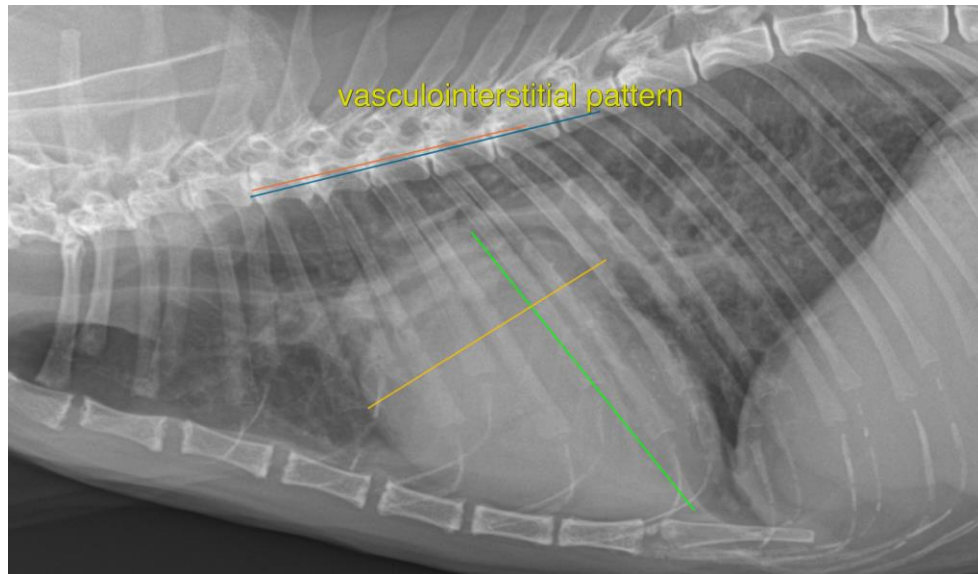
Feline

BREED

Siamese

SEX

Male



AGE

12 Years

The information and recommendations provided are based on the images presented by the referring veterinarian/sonographer. No evaluation can be communicated regarding pathology that was not visible in the image/video clips provided.

INTERPRETED BY

Nele Eley, DVM
Dr. med. Vet. DipECVDI

Thank you for this referral. If the clinical or image interpretation does not parallel your findings or if I can be of any further assistance please contact me.

Nele Eley, DVM, Dr. med. vet., DipECVDI
European Specialist in Veterinary Diagnostic Imaging, Cert. Radiology,
Senior lecturer University of Giessen, Germany, Veterinary Faculty, Department of Radiology
info@sonopath.com

HOSPITAL NAME

Truscott Animal
Hospital

REFERRING VET

Dr. Medhat Meawad

INVOICE

59079

DATE

6-27-23