



PATIENT

Benni Strawn

PRESENTING CLINICAL SIGNS

chronic intermittent vomiting
Abnormal PE/Chem/CBC/UA Results: unremarkable

SPECIES

Feline

RADIOGRAPHIC STUDY OF THE ABDOMEN

Right/left lateral and ventrodorsal whole body views totaling 3 images available for review.

Abdominal interpretation requested.

BREED

Domestic Shorthair

RADIOGRAPHIC FINDINGS

The surrounding bony structures are within normal limits.

SEX

Male Neuter

No abnormalities of the extraabdominal soft tissues are noted. The abdominal wall is smooth and thin.

The serosal detail is maintained throughout the peritoneal and retroperitoneal space.

AGE

3 Years

The liver is appropriate in position, size and presents uniform opacity.

The splenic head is in the anticipated position and within normal limits for size and opacity. The splenic tail is not seen.

INTERPRETED BY

Nele Eley, DVM
Dr. med. Vet. DipECVDI

Both kidneys are seen and present with normal size, shape, delineation and opacity. The urinary bladder is in its anticipated position. No radiopaque calculi are noted throughout the upper and lower urinary tract.

The stomach is postprandial.

HOSPITAL NAME

St. Catherine's Animal
Hospital

The small intestine contains a mix of gas and food. The small intestinal loops are nondilated. No evidence of radiopaque foreign material is seen. There is no evidence of abnormal plication.

A moderate amount of fecal matter and gas are seen within the colon.

REFERRING VET

Dr. Boctor

RADIOGRAPHIC DIAGNOSIS

- Normal radiographic presentation of the abdomen with no evidence of mechanical ileus.

INVOICE

59076

INTERPRETATION OF THE FINDINGS & FURTHER RECOMMENDATIONS

The radiographic study of the abdomen is within normal limits. Evidence of mechanical intestinal obstruction is not found radiographically. Functional ileus remains a potential and other pathologies such as hepatic, pancreatic, and more cannot be ruled out. Further definition by means of ultrasound should be considered in case of persisting clinical signs.

DATE

6-27-23



PATIENT

Benni Strawn

SPECIES

Feline

BREED

Domestic Shorthair

SEX

Male Neuter

AGE

3 Years

INTERPRETED BY

Nele Eley, DVM
Dr. med. Vet. DipECVDI

HOSPITAL NAME

St. Catherine's Animal
Hospital

REFERRING VET

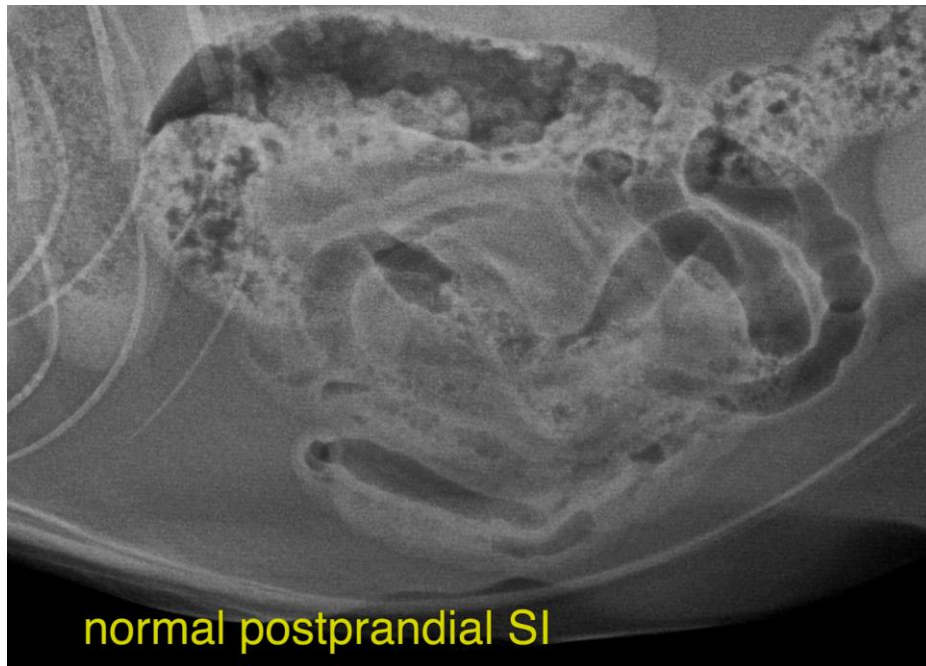
Dr. Boctor

INVOICE

59076

DATE

6-27-23



The information and recommendations provided are based on the images presented by the referring veterinarian/sonographer. No evaluation can be communicated regarding pathology that was not visible in the image/video clips provided.

Thank you for this referral. If the clinical or image interpretation does not parallel your findings or if I can be of any further assistance please contact me.

Nele Eley, DVM, Dr. med. vet., DipECVDI
European Specialist in Veterinary Diagnostic Imaging, Cert. Radiology,
Senior lecturer University of Giessen, Germany, Veterinary Faculty, Department of Radiology
info@sonopath.com