



PATIENT

Thomas Santilli

PRESENTING CLINICAL SIGNS

Pt presented for not eating, low energy, and licking lips. Pt hasn't eaten since yesterday mid-day. Pt has gotten at socks, etc before, but o says he never eats them, just plays with them. Had similar episode last Thursday - v/d, but then resolved. Now back, but not having diarrhea. BW/cpl pending.

SPECIES

Canine

RADIOGRAPHIC STUDY OF THE ABDOMEN

2 Right/left lateral and 1 ventrodorsal view of the abdomen available for review.

BREED

Maltese Mix

RADIOGRAPHIC FINDINGS

The abdominal serosal detail is maintained.

SEX

The patient's body condition score appears to be mildly excessive.

NM

Moderate gastric aerophagia is noted.

AGE

3.5 Years

A mild amount of food is seen within the stomach and condensed within the gastric fundus on the orthogonal view.

The colon contains a large amount inspissated fecal matter.

INTERPRETED BY

Nele Eley, DVM
Dr. med. Vet. DipECVDI

The small intestinal loops are evenly distributed throughout the mid abdomen and mildly turgid in appearance. No evidence of intestinal foreign material, dilation, or plication is seen.

The splenic tail, liver, and urinary bladder present within normal limits.

RADIOGRAPHIC DIAGNOSIS

- Gastric aerophagia and turgid appearance of the non-dilated small intestine.

HOSPITAL NAME

The Pet Hospital of
Stratford

INTERPRETATION OF THE FINDINGS & FURTHER RECOMMENDATIONS

The radiographic study reveals a gastrointestinal maldigestion pattern with no direct signs of mechanical ileus. The colon contains inspissated fecal matter. Small intestinal subileus and functional ileus remain a potential. Further definition by means of abdominal ultrasound could be considered in case of persisting clinical signs in order to rule out partial obstruction, echoarchitectural changes of the gastrointestinal tract's wall, to further assess the gastrointestinal content, and peristalsis, as well as to rule out pathology in other abdominal organs.

REFERRING VET

Dr. Giuliani

INVOICE

59035

DATE

6-26-23



PATIENT

Thomas Santilli

SPECIES

Canine

BREED

Maltese Mix

SEX

NM

AGE

3.5 Years

INTERPRETED BY

Nele Eley, DVM
Dr. med. Vet. DipECVDI

HOSPITAL NAME

The Pet Hospital of
Stratford

REFERRING VET

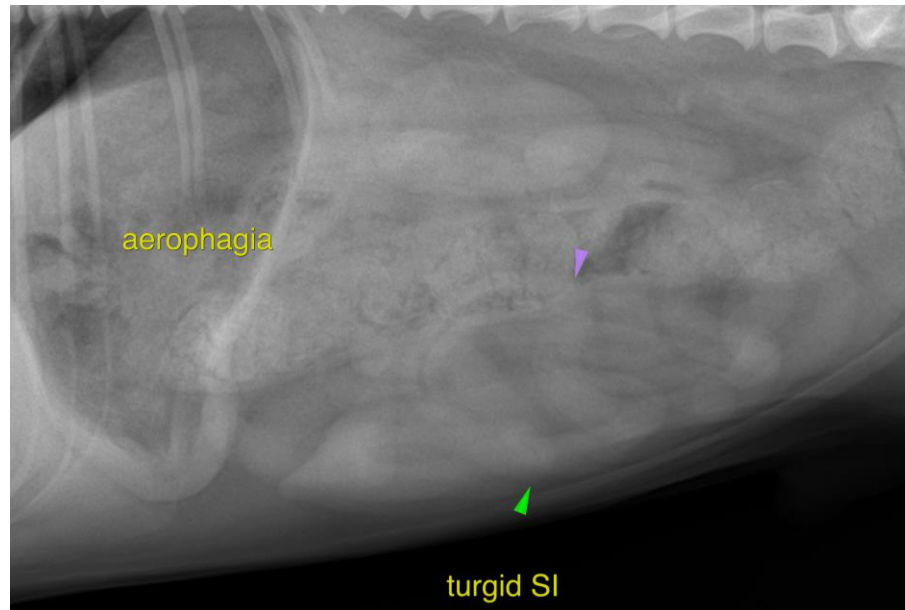
Dr. Giuliani

INVOICE

59035

DATE

6-26-23



The information and recommendations provided are based on the images presented by the referring veterinarian/sonographer. No evaluation can be communicated regarding pathology that was not visible in the image/video clips provided.

Thank you for this referral. If the clinical or image interpretation does not parallel your findings or if I can be of any further assistance please contact me.

Nele Eley, DVM, Dr. med. vet., DipECVDI
European Specialist in Veterinary Diagnostic Imaging, Cert. Radiology,
Senior lecturer University of Giessen, Germany, Veterinary Faculty, Department of Radiology
info@sonopath.com