



PATIENT

Otis Hilfiker

PRESENTING CLINICAL SIGNS

Left sided periorbital swelling. Anesthesia and explore lance of a suspected abscess. Despite antibiotics and non steroidal no improvement.
Abnormal PE/Chem/CBC/UA Results: Neutrophilic Leukocytosis

SPECIES

Canine

COMPUTED TOMOGRAPHIC STUDY OF THE HEAD

Plain and post contrast studies available for review.

BREED

Labrador Retriever

COMPUTED TOMOGRAPHIC FINDINGS

An approximately 4 x 5 cm sized irregular shaped cavitory lesion with fluid attenuating content is seen in the left retrobulbar space. The cavitory lesion presents a contrast negative center with thick peripheral rim enhancement. Extensive perilesional soft tissue swelling is seen. The mass effect causes rostral and dorsal deviation of the left eye. The cavitory lesion itself extends into the retromolar soft tissues. Temporal and periorbital soft tissue swelling are seen. Foreign material cannot be identified within the cavitory lesion.

SEX

MN

The regional left medial retropharyngeal and submandibular lymph nodes present moderate symmetric enlargement with peripheral fat stranding.

AGE

1 Year

COMPUTED TOMOGRAPHIC DIAGNOSIS

- Left sided retrobulbar abscess with extensive peripheral cellulitis and myositis.
- Lymphadenitis of the left medial retropharyngeal and submandibular lymph nodes.

INTERPRETED BY

Nele Eley, DVM
Dr. med. Vet. DipECVDI

INTERPRETATION OF THE FINDINGS & FURTHER RECOMMENDATIONS

The CT findings are compatible with a retrobulbar abscess within the left orbita and left retromolar tissues. Foreign material cannot be identified within the abscess, however, small pieces of migrating foreign material may well have been the cause of the abscess. Small organic pieces may go unnoticed in CT. The foreign material may have migrated already as well. Timely abscess drainage is recommended if not performed already.

HOSPITAL NAME

Southern Oregon
Veterinary Specialty
Center

The findings of the lymph nodes are compatible with reactive or suppurative lymphadenitis.

REFERRING VET

Ravi Seshadri

INVOICE

58996

DATE

6-24-23



PATIENT

Otis Hilfiker

SPECIES

Canine

BREED

Labrador Retriever

SEX

MN

AGE

1 Year

INTERPRETED BY

Nele Eley, DVM
Dr. med. Vet. DipECVDI

HOSPITAL NAME

Southern Oregon
Veterinary Specialty
Center

REFERRING VET

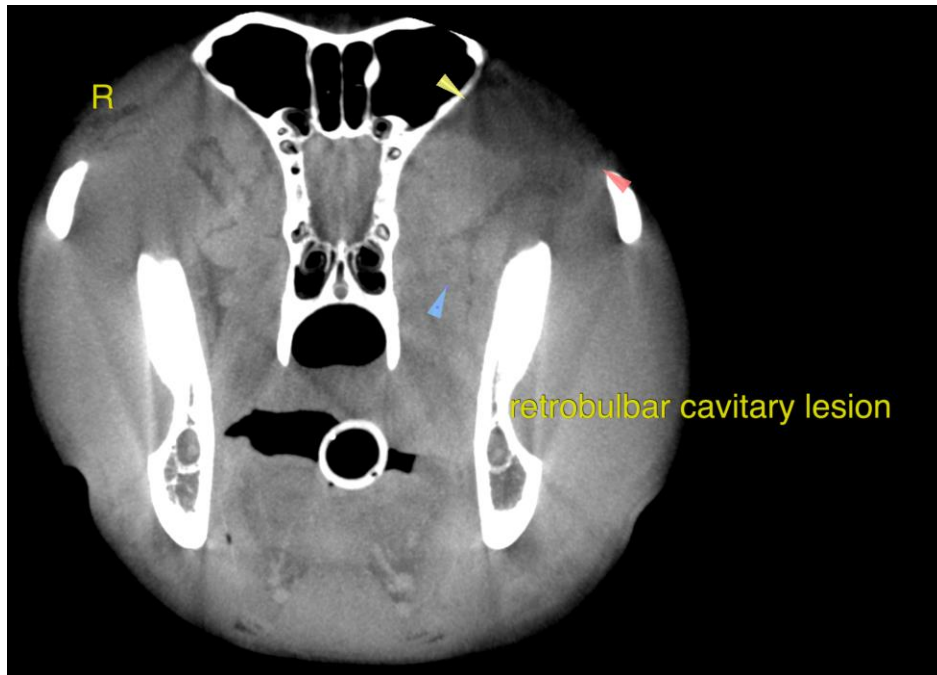
Ravi Seshadri

INVOICE

58996

DATE

6-24-23



The information and recommendations provided are based on the images presented by the referring veterinarian/sonographer. No evaluation can be communicated regarding pathology that was not visible in the image/video clips provided.

Thank you for this referral. If the clinical or image interpretation does not parallel your findings or if I can be of any further assistance please contact me.

Nele Eley, DVM, Dr. med. vet., DipECVDI
European Specialist in Veterinary Diagnostic Imaging, Cert. Radiology,
Senior lecturer University of Giessen, Germany, Veterinary Faculty, Department of Radiology
info@sonopath.com