



**PATIENT PRESENTING CLINICAL SIGNS**

Rex Riddle P is presented with a history of nasal discharge  
 Abnormal PE/Chem/CBC/UA Results: Eosinophils 1529 (0-1200) otherwise CBC WNL, Chemistry WNL GI PCR Positive to Ancylostoma.

**SPECIES COMPUTED TOMOGRAPHIC STUDY OF THE HEAD**

Canine Plain and post contrast studies are available for review.

**BREED COMPUTED TOMOGRAPHIC FINDINGS**

Belgium Malinos The CT study reveals extensive mucosal swelling and fluid accumulation within both nasal cavities. Moderate turbinate destruction is seen accentuating the mid third of both nasal cavities. A moderate amount of fluid attenuating material and mucosal swelling are present within the left and right frontal sinus, L>R. The cribriform plate is intact. Multifocal mineralization of the remaining turbinates is seen.

**SEX** There is no evidence of foreign material or a soft tissue mass.

Male Neutered No significant dental changes are noted.

**AGE** The regional lymph nodes present within normal limits.

4.5 Years The left tympanic bulla is smaller with thicker osseous wall compared with the right tympanic bulla. Both bullae are patent.

**COMPUTED TOMOGRAPHIC DIAGNOSIS**

**INTERPRETED BY**

Nele Eley (Ondreka),  
 DVM Dr. med. vet.,  
 DipECVDI

- Severe chronic destructive rhinosinusitis of both nasal cavities and frontal sinuses.
- Suspect congenital anatomic variation of the tympanic bullae with asymmetry.

**INTERPRETATION OF FINDINGS & FURTHER RECOMMENDATIONS**

**HOSPITAL NAME**

Cooper City Animal  
 Clinic

The CT study reveals chronic bilateral destructive rhinosinusitis. Infectious rhinitis such as fungal infection with aspergillus or other species is a primary differential diagnosis. Chronic bacterial rhinitis cannot be ruled out entirely. Viral infection is considered less likely based on the extent of the destructive changes. Further definition by means of rhinoscopy with sampling is recommended if not performed already.

**REFERRING VET**

Villasmil

**INVOICE**

58952

**DATE**

6-21-23



**PATIENT**

Rex Riddle

**SPECIES**

Canine

**BREED**

Belgium Malinos

**SEX**

Male Neutered

**AGE**

4.5 Years

**INTERPRETED BY**

Nele Eley (Ondreka),  
DVM Dr. med. vet.,  
DipECVDI

**HOSPITAL NAME**

Cooper City Animal  
Clinic

**REFERRING VET**

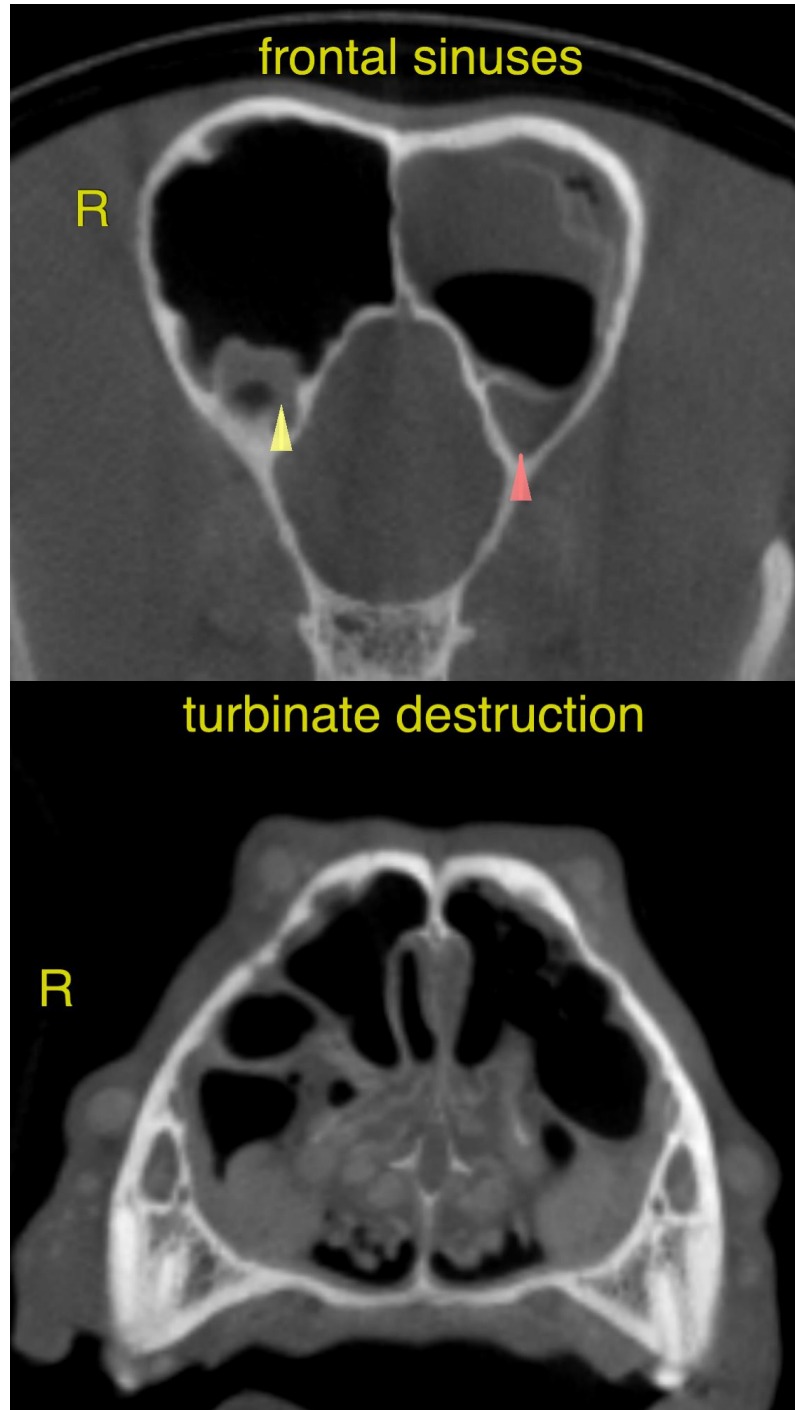
Villasmil

**INVOICE**

58952

**DATE**

6-21-23





**PATIENT** The information and recommendations provided are based on the images presented by the referring veterinarian. No evaluation can be communicated regarding pathology that was not visible in the image/video clips provided.

Rex Riddle

Thank you for this referral. If the clinical or image interpretation does not parallel your findings or if I can be of any further assistance please contact me.

**SPECIES**

Canine

**Nele Eley (Ondreka)**, DVM, Dr. med. vet., DipECVDI  
European Specialist in Veterinary Diagnostic Imaging, Cert. Radiology,  
Senior lecturer University of Giessen/Germany, Veterinary Faculty, Department of Radiology.  
[info@sonopath.com](mailto:info@sonopath.com)

**BREED**

Belgium Malinos

**SEX**

Male Neutered

**AGE**

4.5 Years

**INTERPRETED BY**

Nele Eley (Ondreka),  
DVM Dr. med. vet.,  
DipECVDI

**HOSPITAL NAME**

Cooper City Animal  
Clinic

**REFERRING VET**

Villasmil

**INVOICE**

58952

**DATE**

6-21-23