

**PATIENT**

Leia Heatley

PRESENTING CLINICAL SIGNS

Chronic CCL trauma since Nov 2022, favoring Left rear leg
Abnormal PE/Chem/CBC/UA Results: Restriction in the ROM of the Left knee. Large medial buttress. Positive Cranial drawer but limited due to fibrosis, Positive CTT.

SPECIES

Canine

ULTRASONOGRAPHIC FINDINGS**Left Stifle****BREED**

Lg Lab Mix

Moderate thickening of the left stifle joint's synovium with synovial proliferations is seen. There appears to be thickening of the joint capsule. A large amount of periarticular osteophytes are present. There is heterogeneity of the infrapatellar fat pad. A short stump of irregular fibers is seen at the intercondylar eminence of the tibia representing the stump of the left cranial cruciate ligament. The caudal horn of the medial meniscus is ill-defined with irregular surface and strong internal heterogeneity. Hypochoic interruptions of the medial meniscal tissue appear to be present. Internal heterogeneity of the lateral meniscus is seen as well.

SEX

FS

ULTRASONOGRAPHIC DIAGNOSIS

- Moderate to severe osteoarthritis of the left stifle joint with complete rupture of the cruciate ligament and meniscal injury, synovialitis, osteophytosis, and effusion as well as capsular fibrosis.

AGE

5 Years, 5 Months

INTERPRETATION OF THE FINDINGS & FURTHER RECOMMENDATIONS

Moderate to severe osteoarthritic changes of the left stifle joint are seen in conjunction with cranial cruciate ligament pathology. The findings suggest full rupture of the cruciate ligament as well as injury of the caudal horn of the medial meniscus. The internal heterogeneity of the lateral meniscus is likely to represent degeneration.

INTERPRETED BY

Nele Eley, DVM
Dr. med. Vet. DipECVDI

HOSPITAL NAME

Westview Veterinary
Hospital

REFERRING VET

Dr. Brian Barnes

INVOICE

58955

DATE

6-21-23



PATIENT

Leia Heatley

SPECIES

Canine

BREED

Lg Lab Mix

SEX

FS

AGE

5 Years, 5 Months

INTERPRETED BY

Nele Eley, DVM
Dr. med. Vet. DipECVDI

HOSPITAL NAME

Westview Veterinary
Hospital

REFERRING VET

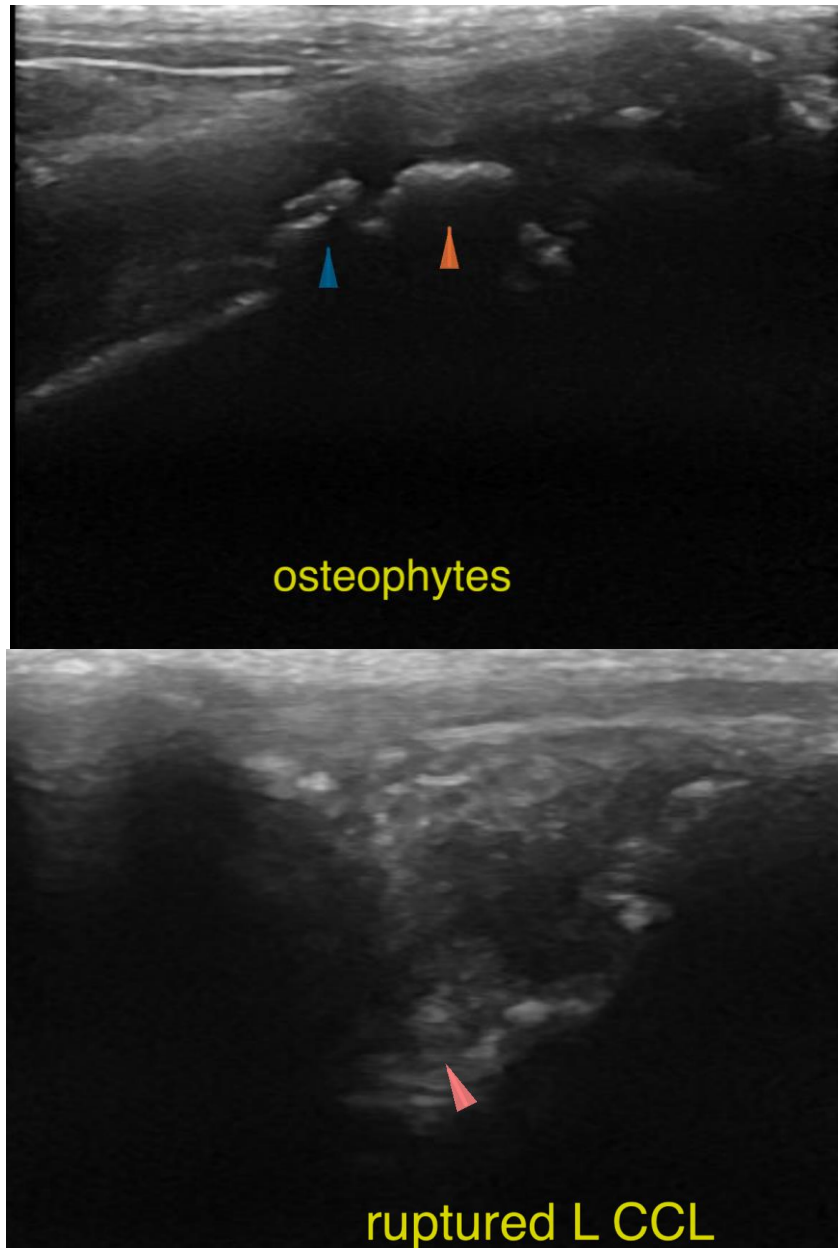
Dr. Brian Barnes

INVOICE

58955

DATE

6-21-23





PATIENT

Leia Heatley

SPECIES

Canine

BREED

Lg Lab Mix

SEX

FS

AGE

5 Years, 5 Months

INTERPRETED BY

Nele Eley, DVM
Dr. med. Vet. DipECVDI

HOSPITAL NAME

Westview Veterinary
Hospital

REFERRING VET

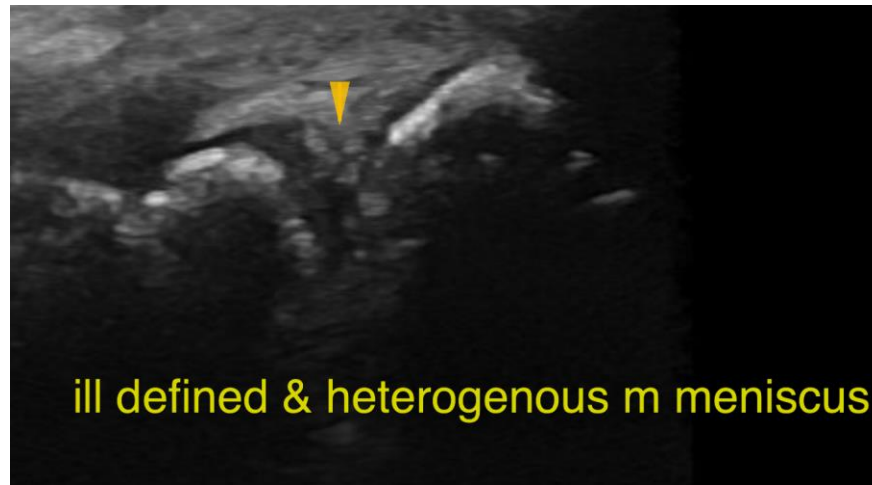
Dr. Brian Barnes

INVOICE

58955

DATE

6-21-23



The information and recommendations provided are based on the images presented by the referring veterinarian/sonographer. No evaluation can be communicated regarding pathology that was not visible in the image/video clips provided.

Thank you for this referral. If the clinical or image interpretation does not parallel your findings or if I can be of any further assistance please contact me.

Nele Eley, DVM, Dr. med. vet., DipECVDI
European Specialist in Veterinary Diagnostic Imaging, Cert. Radiology,
Senior lecturer University of Giessen, Germany, Veterinary Faculty, Department of Radiology
info@sonopath.com