

**PATIENT PRESENTING CLINICAL SIGNS**

Bello Cangelosi P has a history of severe bilateral nasal green discharge for several weeks, P was treated with baytril and clavamox 14 and 10 days respectively, p was on steroids and the discharge persist.
Abnormal PE/Chem/CBC/UA Results: BW : ALT 185H, ALP 309H otherwise WNL

SPECIES COMPUTED TOMOGRAPHIC STUDY OF THE HEAD

Canine Plain and post contrast studies are available for review.

BREED COMPUTED TOMOGRAPHIC FINDINGS

Bull Terrier Moderate mucosal swelling and fluid accumulation are noted within both nasal cavities. Mild multifocal turbinate destruction is seen bilaterally as well. The bilateral frontal sinuses present mucosal swelling. The cribriform plate is intact. There is no evidence of bone destruction.

SEX Both medial retropharyngeal lymph nodes present mild symmetric enlargement.

Male Neutered

COMPUTED TOMOGRAPHIC DIAGNOSIS

- AGE**
- Moderate chronic bilateral rhinosinusitis with mild destructive component.
 - Mild bilaterally symmetric medial retropharyngeal lymphadenomegaly.

13 Years **INTERPRETATION OF FINDINGS & FURTHER RECOMMENDATIONS**

INTERPRETED BY

Nele Eley (Ondreka),
DVM Dr. med. vet.,
DipECVDI

The CT findings are compatible with chronic rhinosinusitis with destructive component. Chronic bacterial rhinitis is considered likely. Fungal rhinitis cannot be ruled out entirely as a differential diagnosis. Further definition by means of rhinoscopy and sampling is recommended if not performed already.

The lymph node changes are mild and compatible with reactive lymphadenitis.

HOSPITAL NAME

Mobile Pet Imaging

REFERRING VET

Villasmil

INVOICE

58957

DATE

6-21-23



PATIENT

Bello Cangelosi

SPECIES

Canine

BREED

Bull Terrier

SEX

Male Neutered

AGE

13 Years

INTERPRETED BY

Nele Eley (Ondreka),
DVM Dr. med. vet.,
DipECVDI

HOSPITAL NAME

Mobile Pet Imaging

REFERRING VET

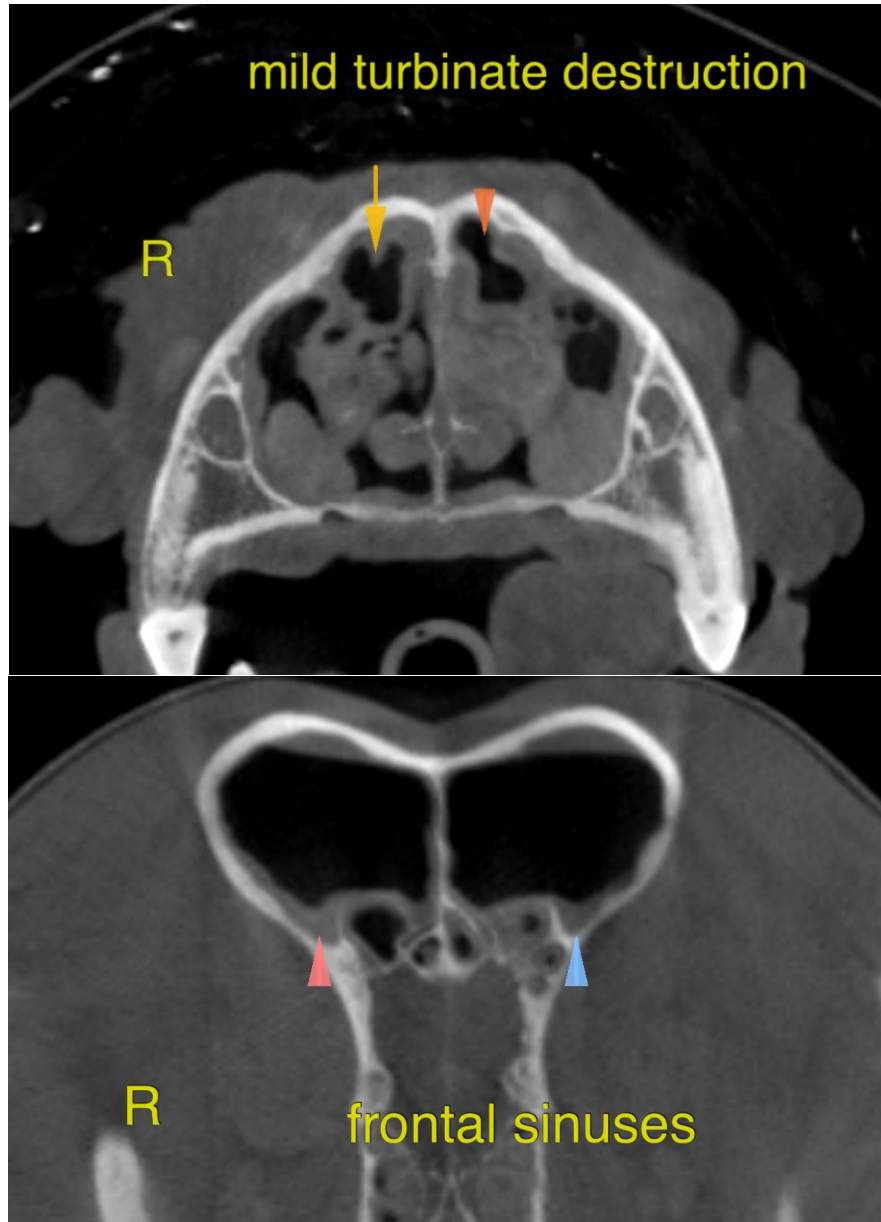
Villasmil

INVOICE

58957

DATE

6-21-23



**PATIENT**

Bello Cangelosi

The information and recommendations provided are based on the images presented by the referring veterinarian. No evaluation can be communicated regarding pathology that was not visible in the image/video clips provided.

SPECIES

Canine

Thank you for this referral. If the clinical or image interpretation does not parallel your findings or if I can be of any further assistance please contact me.

BREED

Bull Terrier

Nele Eley (Ondreka), DVM, Dr. med. vet., DipECVDI
European Specialist in Veterinary Diagnostic Imaging, Cert. Radiology,
Senior lecturer University of Giessen/Germany, Veterinary Faculty, Department of Radiology.
info@sonopath.com

SEX

Male Neutered

AGE

13 Years

INTERPRETED BY

Nele Eley (Ondreka),
DVM Dr. med. vet.,
DipECVDI

HOSPITAL NAME

Mobile Pet Imaging

REFERRING VET

Villasmil

INVOICE

58957

DATE

6-21-23