



PATIENT PRESENTING CLINICAL SIGNS

Hazel Blakely
 Angie and her husband were not home, and May heard the dogs yipping. They are kept outside in a kennel which they have learned how to escape. May(the neighbor) saw Hazel being stomped by a deer. The other dog is fine because he ran off, but Hazel had run about 3 acres down. May approved xrays today. Radiographs were also sent to VSR as Hazel was transferred to the ER today for supportive care until the orthopedic consultation.

SPECIES
 Canine
 Abnormal PE/Chem/CBC/UA Results: NON-AMBULATORY, WILL STAND BUT PAINFUL ON RIGHT FRONT AND LEFT REAR RIGHT EYE BRUSING TO CONJUNCTIVA AND SOME DEBRIS IN EYE UNCOMFORTABLE TO PALPATION OF ABDOMEN AND IN GENERAL

BREED RADIOGRAPHIC STUDY OF THE THORAX & ABDOMEN

Shih Tzu
 Lateral and dorsoventral whole body images and ventrodorsal view of the pelvis totaling 5 images available for review.

SEX RADIOGRAPHIC FINDINGS

Female
Thorax

The radiographic study reveals fracture of ribs 1-3 on the right side within their proximal third. The 7th rib is fractured in its mid third. Medial deviation of the ribcage is seen at the same level with regional pleural effusion, retraction of the lung lobes from the thoracic wall, and consolidation of the right lung accentuating the right middle lobe.

AGE
 1 Year, 8 Months

INTERPRETED BY
 Mild mid thoracic lordosis is present; however, no vertebral subluxation or fracture can be identified.

Nele Eley, DVM
 Dr. med. Vet. DipECVDI

Abdomen

The abdominal serosal detail appears to be within normal limits.

HOSPITAL NAME

Elizabeth Animal Hospital

No fracture of the lumbar spine is seen.

The sacroiliac joints present within normal limits.

REFERRING VET

Kim Allyn, DVM

A short oblique fracture of the right iliac bone cranial to the acetabulum is seen with moderate medial and cranial deviation of the right hemipelvis. A concurrent fracture of the cranial ramus of the right pubic bone is present. There appears to be no involvement of the right acetabulum.

RADIOGRAPHIC DIAGNOSIS

- INVOICE**
- Serial rib fracture of ribs 1-3 and rib 7 on the right side with pulmonary contusion/hemorrhage and regional pleural effusion within the right pleural cavity.
 - Fracture of the right hemipelvis with involvement of the iliac and pubic bones with moderate medial and cranial displacement of the right hemipelvis.

52291

DATE INTERPRETATION OF THE FINDINGS & FURTHER RECOMMENDATIONS

6-2-22
 The radiographic study reveals acute traumatic osseous injury of the ribcage on the right side involving the ribs 1-3 and 7. Concurrent pulmonary contusion and/or hemorrhage is seen as well



PATIENT

as mild regional pleural effusion suggestive for hemorrhage.

Hazel Blakely

I cannot identify a vertebral fracture or luxation/subluxation. However, concurrent spinal injury including traumatic disc hernia cannot be ruled out entirely. Consider cross sectional imaging should the patient's non-ambulatory status be due to paresis / paralysis.

SPECIES

Canine

The fracture of the right ilium appears to spare the acetabulum. Concurrent pubic fracture is seen and there is mild to moderate narrowing of the pelvic canal due to medial and cranial displacement of the right hemipelvis.

BREED

Shih Tzu

SEX

Female

AGE

1 Year, 8 Months

INTERPRETED BY

Nele Eley, DVM
Dr. med. Vet. DipECVDI

HOSPITAL NAME

Elizabeth Animal
Hospital

REFERRING VET

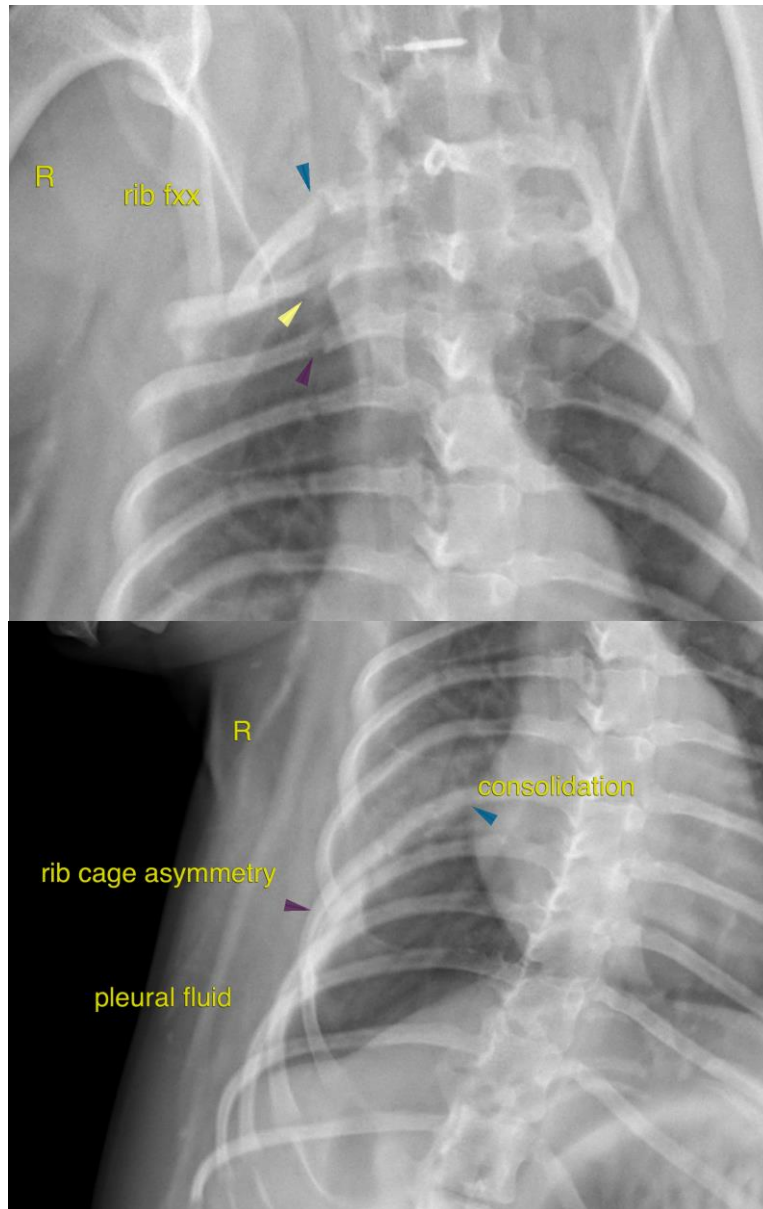
Kim Allyn, DVM

INVOICE

52291

DATE

6-2-22





PATIENT

Hazel Blakely

SPECIES

Canine

BREED

Shih Tzu

SEX

Female

AGE

1 Year, 8 Months

INTERPRETED BY

Nele Eley, DVM
Dr. med. Vet. DipECVDI

HOSPITAL NAME

Elizabeth Animal
Hospital

REFERRING VET

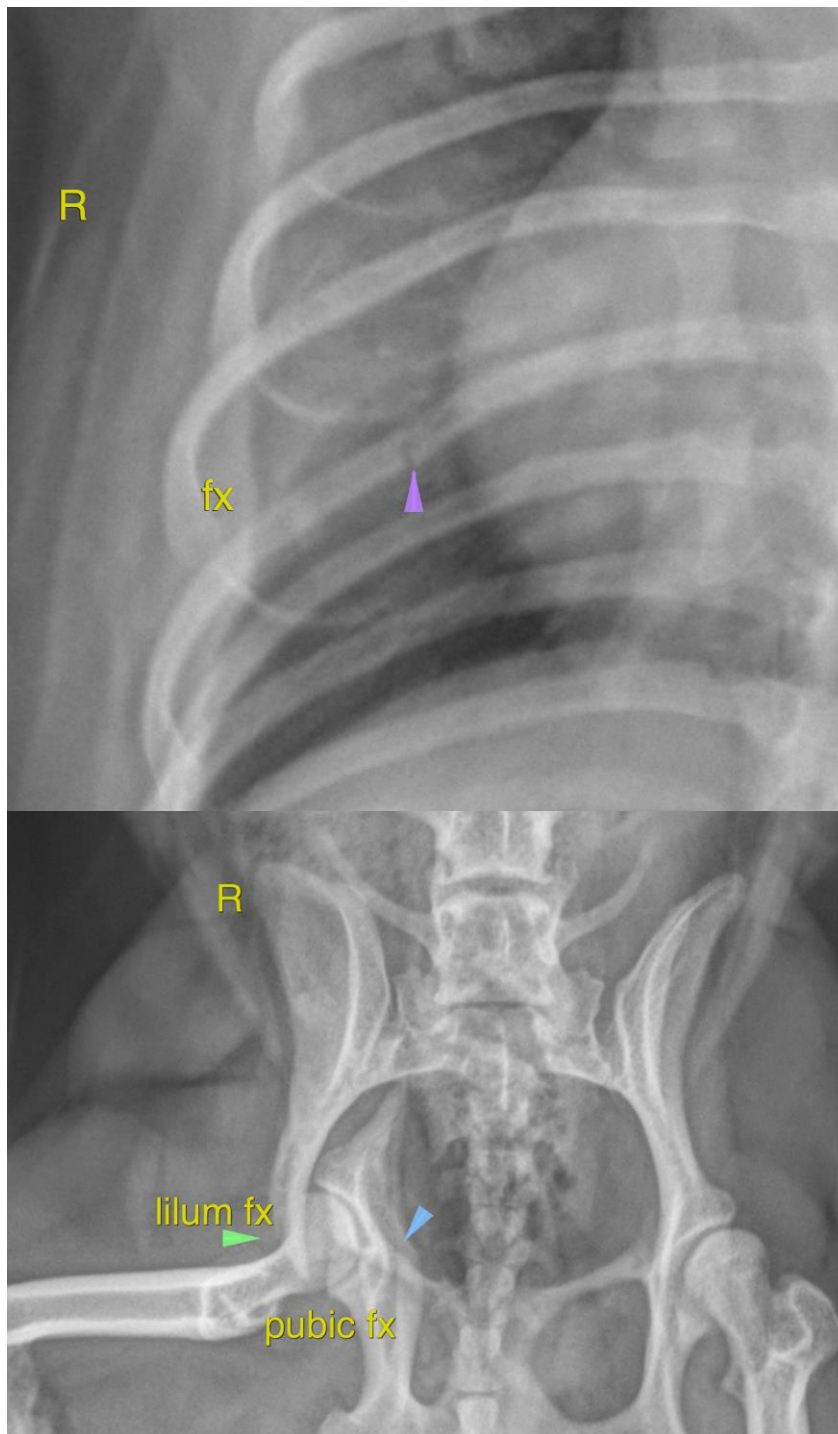
Kim Allyn, DVM

INVOICE

52291

DATE

6-2-22





PATIENT

Hazel Blakely

The information and recommendations provided are based on the images presented by the referring veterinarian/sonographer. No evaluation can be communicated regarding pathology that was not visible in the image/video clips provided.

Thank you for this referral. If the clinical or image interpretation does not parallel your findings or if I can be of any further assistance please contact me.

SPECIES

Canine

Nele Eley, DVM, Dr. med. vet., DipECVDI
European Specialist in Veterinary Diagnostic Imaging, Cert. Radiology,
Senior lecturer University of Giessen, Germany, Veterinary Faculty, Department of Radiology
Nele.Eley@sonopath.com

BREED

Shih Tzu

SEX

Female

AGE

1 Year, 8 Months

INTERPRETED BY

Nele Eley, DVM
Dr. med. Vet. DipECVDI

HOSPITAL NAME

Elizabeth Animal
Hospital

REFERRING VET

Kim Allyn, DVM

INVOICE

52291

DATE

6-2-22