

**PATIENT PRESENTING CLINICAL SIGNS**

Cielo Mansell Right patellar luxation. Further evaluation before surgical intervention.

COMPUTED TOMOGRAPHIC STUDY OF THE STIFLE JOINTS**SPECIES**

Canine

Plain and post IV contrast study of the hind limbs available for review.

COMPUTED TOMOGRAPHIC FINDINGS**BREED**

Mix

Right Stifle

The patella is in situ. Moderate osseous remodeling of the proximal and distal poles of the patella is seen. There also is a moderate amount of osteophytes lining the lateral and medial aspect as well as the proximal extent of the femoral trochlea. Mild articular swelling is seen as well as moderate periarticular bone remodeling in the right stifle joint. No evidence of angular limb deformity is noted.

SEX

Neutered Male

The conformation of the femur and tibia appears to be within normal limits and bilaterally symmetric.

No evidence of concurrent canine hip dysplasia is noted.

AGE

2 Years

The right hind limb presents mild generalized muscle atrophy.

Left Stifle

The left stifle joint presents within normal limits.

INTERPRETED BY

Nele Eley (Ondreka),
DVM Dr. med. vet.,
DipECVDI

COMPUTED TOMOGRAPHIC DIAGNOSIS

- Mild to moderate right stifle osteoarthritis with accentuation of the femoral patella joint.
- Mild disuse atrophy of the right hind limb musculature.

HOSPITAL NAME

Mobile Pet Imaging

INTERPRETATION OF FINDINGS & FURTHER RECOMMENDATIONS

The CT study reveals moderate osteoarthritic changes of the right femoral patella joint compatible with the history of patella luxation. At the time of the CT examination, the patella was in situ. No evidence of angular limb deformity was noted and no overt deformity of the patella groove or patella itself were seen.

REFERRING VET

Meaux

The right hind limb presents mild generalized muscle atrophy compatible with disuse.

INVOICE

52286

DATE

6-2-22



PATIENT

Cielo Mansell

SPECIES

Canine

BREED

Mix

SEX

Neutered Male

AGE

2 Years

INTERPRETED BY

Nele Eley (Ondreka),
DVM Dr. med. vet.,
DipECVDI

HOSPITAL NAME

Mobile Pet Imaging

REFERRING VET

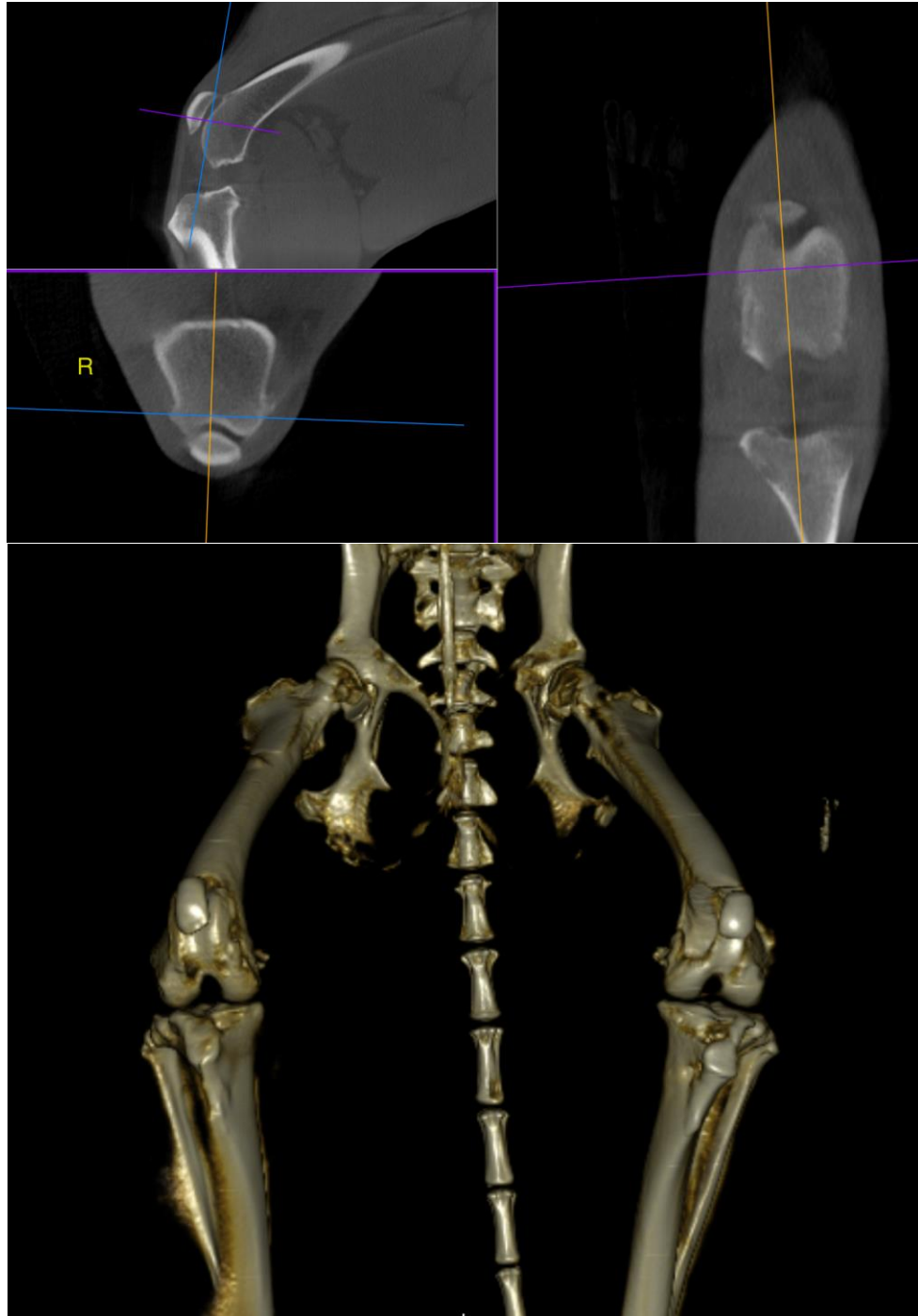
Meaux

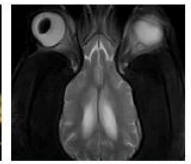
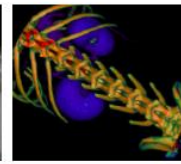
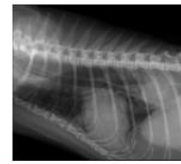
INVOICE

52286

DATE

6-2-22





PATIENT

Cielo Mansell

SPECIES

Canine

BREED

Mix

SEX

Neutered Male

AGE

2 Years

INTERPRETED BY

Nele Eley (Ondreka),
DVM Dr. med. vet.,
DipECVDI

HOSPITAL NAME

Mobile Pet Imaging

REFERRING VET

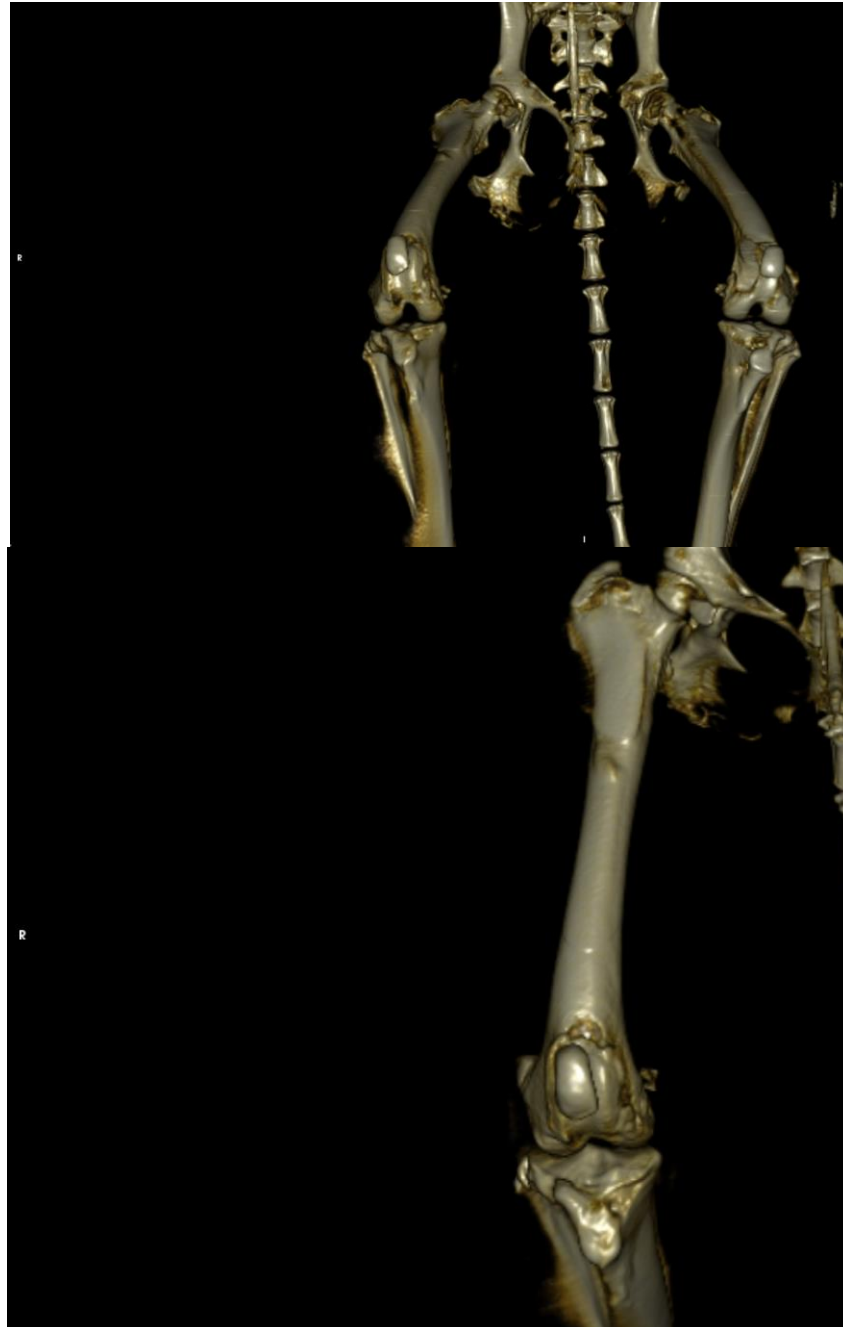
Meaux

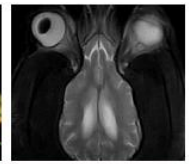
INVOICE

52286

DATE

6-2-22





PATIENT

Cielo Mansell

SPECIES

Canine

BREED

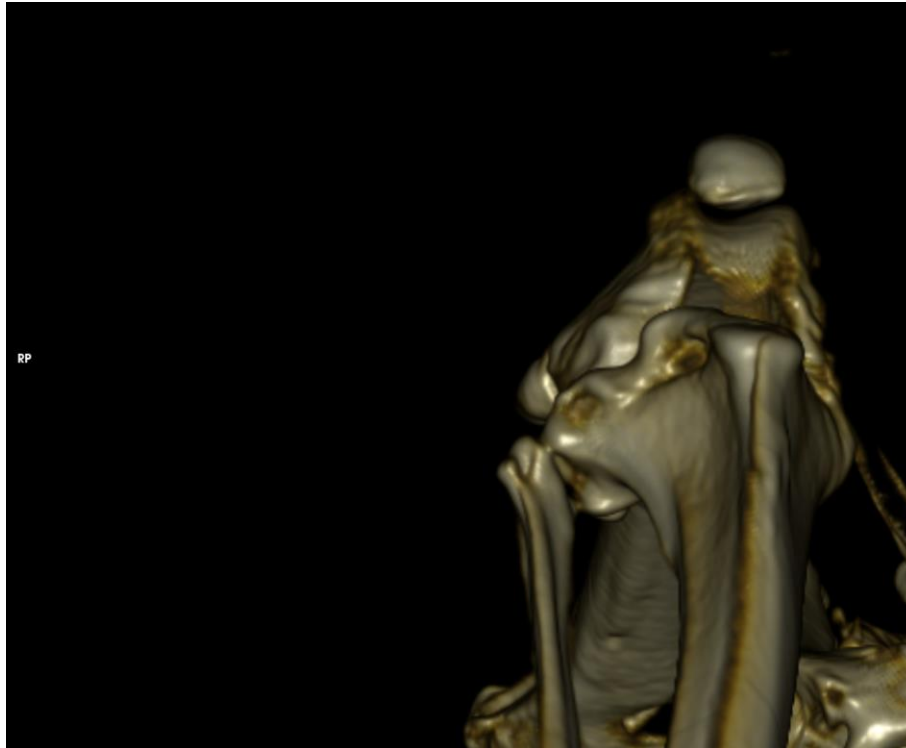
Mix

SEX

Neutered Male

AGE

2 Years



INTERPRETED BY

Nele Eley (Ondreka),
DVM Dr. med. vet.,
DipECVDI

The information and recommendations provided are based on the images presented by the referring veterinarian. No evaluation can be communicated regarding pathology that was not visible in the image/video clips provided.

Thank you for this referral. If the clinical or image interpretation does not parallel your findings or if I can be of any further assistance please contact me.

HOSPITAL NAME

Mobile Pet Imaging

Nele Eley (Ondreka), DVM, Dr. med. vet., DipECVDI
European Specialist in Veterinary Diagnostic Imaging, Cert. Radiology,
Senior lecturer University of Giessen/Germany, Veterinary Faculty, Department of Radiology.
Nele.Eley@sonopath.com

REFERRING VET

Meaux

INVOICE

52286

DATE

6-2-22