SonoPath Teleradiology

EDUCATIONAL TELECONSULTATION SERVICES™

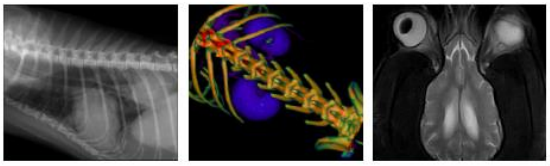

SonoPath.com
1-800-838-4268 info@sonopath.com

PATIENT

Gaia Robson

SPECIES

Ferret

BREED

Ferret

SEX

Spayed Female

AGE

1 Year, 10 Months

INTERPRETED BY

Nele Eley, DVM
Dr. med. Vet. DipECVDI

HOSPITAL NAME

Aloha Pet & Bird Hospital

REFERRING VET

Dr. Dan Pepen

INVOICE

58889

DATE

6-19-23

PRESENTING CLINICAL SIGNS

History of left sided rostral maxillary swelling. Partial improvement w/ antibiotics. Fna inconclusive. Rule out tooth root abscess vs. Fb

COMPUTED TOMOGRAPHIC STUDY OF THE HEAD

Plain and post contrast studies available for review.

COMPUTED TOMOGRAPHIC FINDINGS

Extensive soft tissue swelling is seen lateral to the left rostral maxilla.

Widening of the pulpal cavity of the triadan 204 with gas being present within the pulpal cavity is seen. Regional osteolysis is seen level with the caudal to the alveolus of the triadan 204. No significant nasal soft tissue swelling is noted. Increased contrast enhancement with nonuniform pattern is noted on the post contrast study in the region of the soft tissue swelling paralleling the left rostral maxilla.

No significant regional lymphadenomegaly is noted.

A moderate amount of hypoattenuating contrast negative material is seen medially within the left external auditory meatus as well as within the mesotympanum of the left tympanic bulla.

COMPUTED TOMOGRAPHIC DIAGNOSIS

- Chronic pulpitis with regional osteitis and cellulitis associated with the triadan 204.
- Left hand sided otitis externa and media.

INTERPRETATION OF THE FINDINGS & FURTHER RECOMMENDATIONS

The CT findings are compatible with pulpitis, tooth root abscessation, and regional osteitis emerging from the triadan 204. Extensive peripheral cellulitis with abscess formation is seen. Consider surgical revision with dental extraction.

Otoscopic workup should be considered as well.

SonoPath Teleradiology

EDUCATIONAL TELECONSULTATION SERVICES™

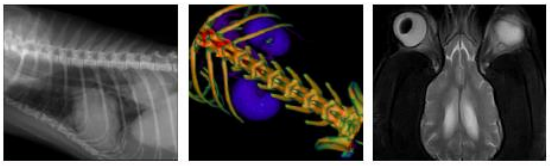

SonoPath.com
1-800-838-4268 info@sonopath.com

PATIENT

Gaia Robson

SPECIES

Ferret

BREED

Ferret

SEX

Spayed Female

AGE

1 Year, 10 Months

INTERPRETED BY

Nele Eley, DVM
Dr. med. Vet. DipECVDI

HOSPITAL NAME

Aloha Pet & Bird Hospital

REFERRING VET

Dr. Dan Pepen

INVOICE

58889

DATE

6-19-23

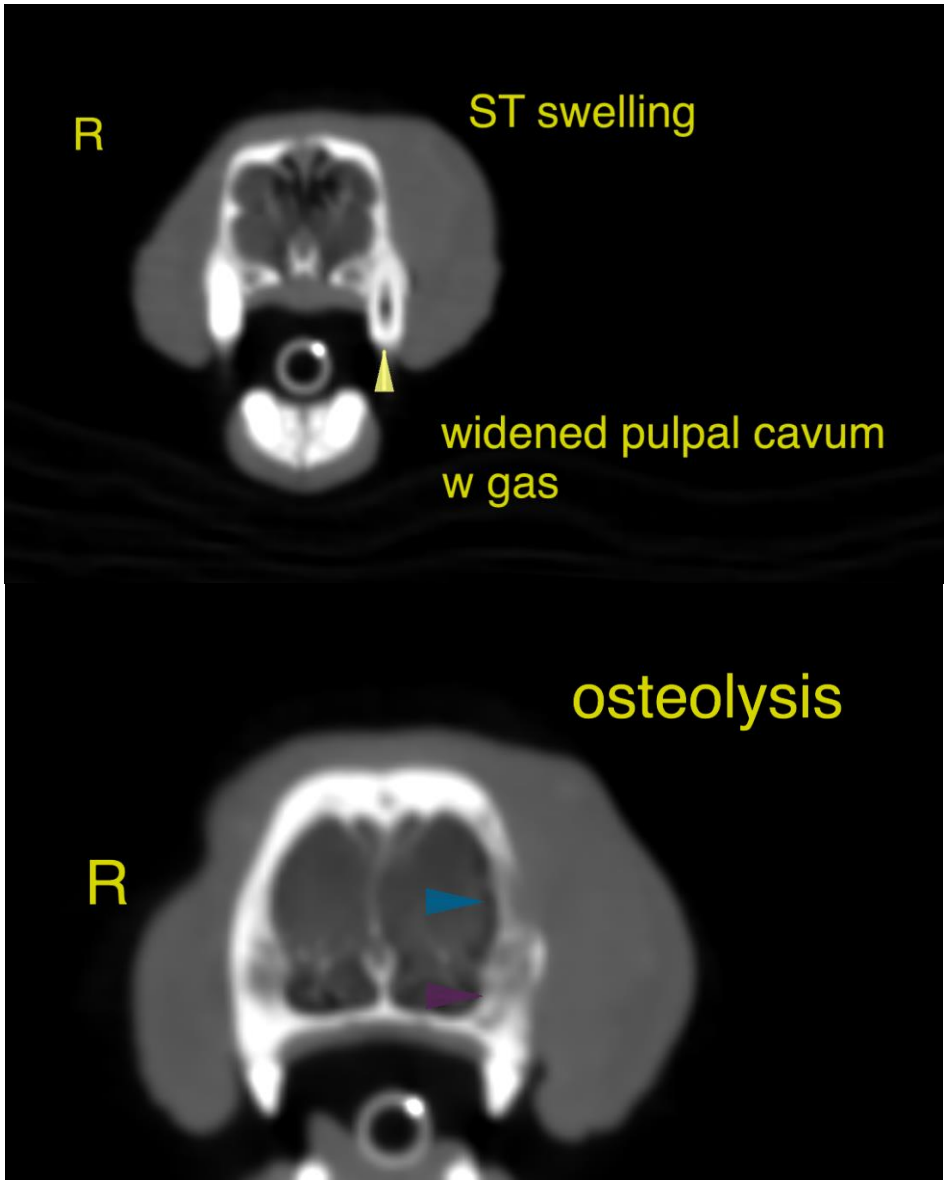

SonoPath Teleradiology

EDUCATIONAL TELECONSULTATION SERVICES™

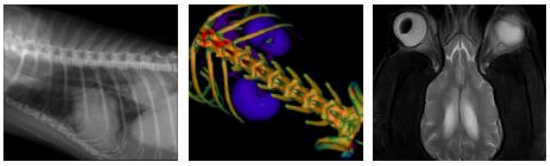

SonoPath.com
1-800-838-4268 info@sonopath.com

PATIENT

Gaia Robson

SPECIES

Ferret

BREED

Ferret

SEX

Spayed Female

AGE

1 Year, 10 Months

INTERPRETED BY

Nele Eley, DVM
Dr. med. Vet. DipECVDI

HOSPITAL NAME

Aloha Pet & Bird Hospital

REFERRING VET

Dr. Dan Pepen

INVOICE

58889

DATE

6-19-23

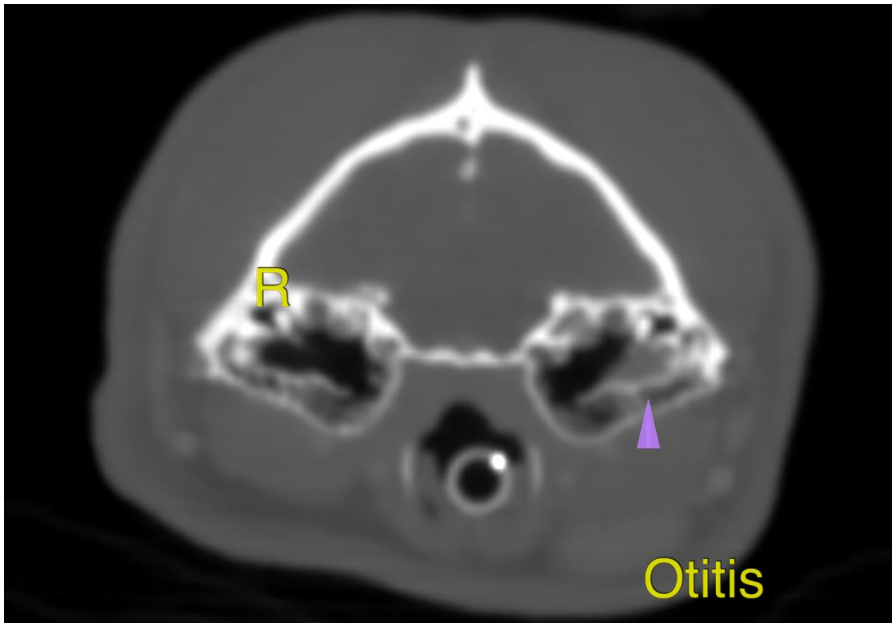

The information and recommendations provided are based on the images presented by the referring veterinarian/sonographer. No evaluation can be communicated regarding pathology that was not visible in the image/video clips provided.

Thank you for this referral. If the clinical or image interpretation does not parallel your findings or if I can be of any further assistance please contact me.

Nele Eley, DVM, Dr. med. vet., DipECVDI
European Specialist in Veterinary Diagnostic Imaging, Cert. Radiology,
Senior lecturer University of Giessen, Germany, Veterinary Faculty, Department of Radiology
info@sonopath.com