



PATIENT PRESENTING CLINICAL SIGNS

Ava Pelletier
 Increased coughing and gagging the past month. Happens if barking, excited, moving or first thing in the morning. Also has history of collapsing trachea. Purchased OTC throat soothing drops but doesn't seem to help. Seems to also happen after drinking, hacking clear liquid. Seems to be drinking more water when at bowl but no increase in frequency. Decreased appetite, only eating once daily instead of three times like usual.

SPECIES

Canine
 Abnormal PE/Chem/CBC/UA Results: Heart/Cardio- shaking, difficulty to auscult murmur. Lungs clear bilaterally, no coughing during appointment. OD: missing, OS: mature cataract, BLIND. Thinned hair coat.

BREED

Chihuahua

RADIOGRAPHIC STUDY OF THE THORAX

Right/left lateral and ventrodorsal whole body views totaling 3 images available for review.

SEX

Thoracic read requested.

Spayed Female

RADIOGRAPHIC FINDINGS

The degree of pulmonary inflation varies between moderate and fair.

AGE

15 Years, 7 Months

Moderate collapse of the caudal cervical trachea is seen level with the thoracic inlet and more pronounced on the expiratory view. Mild concurrent bronchial collapse is noted in the more inspiratory view.

INTERPRETED BY

**Nele Eley, DVM
 Dr. med. Vet. DipECVCI**

The cardiovascular structures present within normal limits. The vertebral heart score is 9. No significant chamber enlargement is seen. The pulmonary vasculature presents within normal limits.

A mild generalized bronchial lung pattern with moderate caudodorsally accentuated peribronchial cuffing is seen.

HOSPITAL NAME

**POCONO PEAK
 VETERINARY
 CENTER**

There is no evidence of mediastinal lymphadenomegaly.

The patient's body condition score appears to be mildly excessive.

Moderate generalized hepatomegaly with slightly rounded lobar margins is noted.

REFERRING VET

Nicole Norris-Carney

RADIOGRAPHIC DIAGNOSIS

- Dynamic tracheal disease affecting the caudal cervical trachea.
- Bronchial lung pattern with caudodorsally accentuated peribronchial cuffing.
- Hepatomegaly.

INVOICE

58925

INTERPRETATION OF THE FINDINGS & FURTHER RECOMMENDATIONS

The radiographic study confirms present of dynamic tracheal disease. Mild concurrent bronchial collapse of the main stem bronchi appears to be present as well. Degenerative bronchomalacia is the most likely underlying cause of the tracheal (and bronchial) collapse.

DATE

6-19-23

There is no radiographic evidence of cardiovascular pathology.



PATIENT

Ava Pelletier

The findings of the bronchial tree support the presence of active lower airway disease such as eosinophilic / allergic bronchopneumopathy or infectious bronchitis including viral, bacterial, and less likely parasitic. Further definition by means of upper and lower airway endoscopy with sampling could be considered if not performed already.

SPECIES

Canine

The changes of the liver suggest presence of diffuse parenchymal disease such as metabolic, endocrine, inflammatory/infectious, or neoplastic. Correlation with the laboratory values recommended. Further definition by means of abdominal ultrasound could be considered as well.

BREED

Chihuahua

SEX

Spayed Female

AGE

15 Years, 7 Months

INTERPRETED BY

Nele Eley, DVM
Dr. med. Vet. DipECVDI

HOSPITAL NAME

POCONO PEAK
VETERINARY
CENTER

REFERRING VET

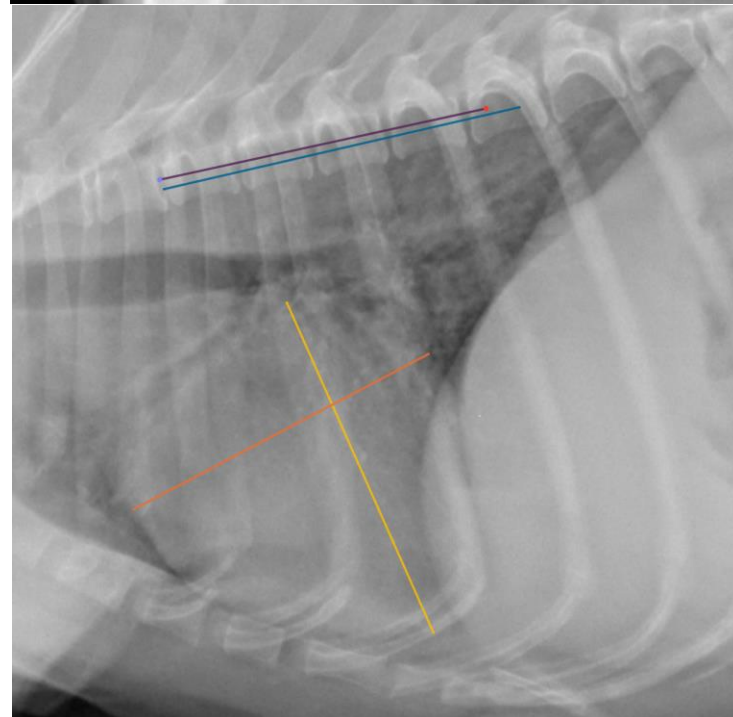
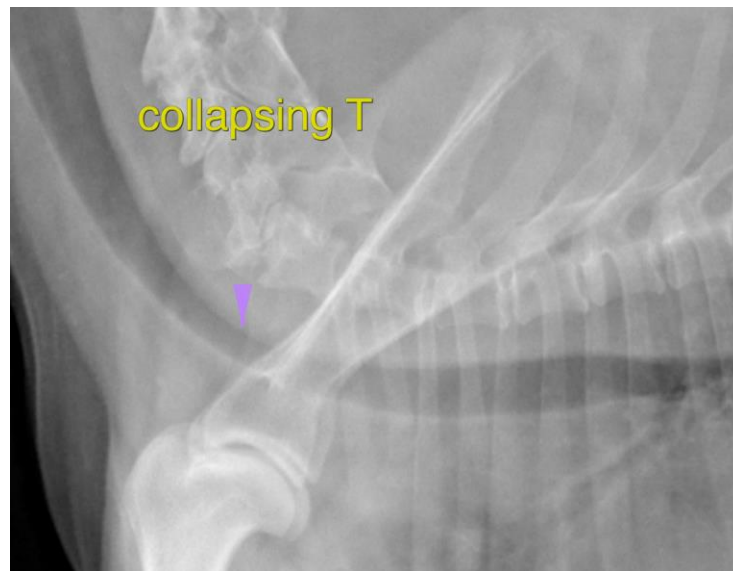Nicole Norris-Carney

INVOICE

58925

DATE

6-19-23





PATIENT

Ava Pelletier

The information and recommendations provided are based on the images presented by the referring veterinarian/sonographer. No evaluation can be communicated regarding pathology that was not visible in the image/video clips provided.

SPECIES

Canine

Thank you for this referral. If the clinical or image interpretation does not parallel your findings or if I can be of any further assistance please contact me.

BREED

Chihuahua

Nele Eley, DVM, Dr. med. vet., DipECVDI
European Specialist in Veterinary Diagnostic Imaging, Cert. Radiology,
Senior lecturer University of Giessen, Germany, Veterinary Faculty, Department of Radiology
info@sonopath.com

SEX

Spayed Female

AGE

15 Years, 7 Months

INTERPRETED BY

Nele Eley, DVM
Dr. med. Vet. DipECVDI

HOSPITAL NAME

POCONO PEAK
VETERINARY
CENTER

REFERRING VET

Nicole Norris-Carney

INVOICE

58925

DATE

6-19-23