



**PATIENT**

Mitizi Obermiller

**PRESENTING CLINICAL SIGNS**

P presented to another ER on 6/10 for vestibular signs - treated with a cerenia injection and started on meclizine. Today had acute swelling of R eye and went to Animal Eye in Maitland - diagnosed with nystagmus, retrobulbar mass, facial nerve paralysis, vestibular disease and a corneal ulcer on R eye. CT or MRI and referral to specialist was recommended. O could not get appointment for imaging until 6/20 - came here for CT

**SPECIES**

Canine

Abnormal PE/Chem/CBC/UA Results: Significant bupophthalmos of OD and swelling around eye; no nystagmus on exam but has been present at other visits. Otherwise exam NSF. Chem and EPOC WNL

**BREED**

Pug

**COMPUTED TOMOGRAPHIC STUDY OF THE HEAD**

Plain and post contrast studies available for review.

**SEX**

Female Spayed

**COMPUTED TOMOGRAPHIC FINDINGS**

A vertically elongated ovoid cavitory lesion of approximately 3 cm height and 1.5 cm width is seen in the right retrobulbar soft tissues. The cavity presents extension into the temporal muscle as well as into the retromolar soft tissues which present extensive swelling. Peripheral rim enhancement is seen. The content of the cavity is fluid attenuating and contrast negative. There is moderate right sided exophthalmos. No evidence of foreign material is seen.

**AGE**

7

The right submandibular, right medial retropharyngeal, and right parotid lymph nodes present mild symmetric enlargement.

**INTERPRETED BY**

Nele Eley, DVM  
Dr. med. Vet. DipECVDI

The right tympanic bulla is filled with fluid attenuating contrast negative material. The lumen of the medial right external auditory meatus is obliterating with fluid attenuating contrast negative material as well.

**HOSPITAL NAME**

Animal Emergency  
Hospital Volusia

Mild increased contrast enhancement is seen in the region of the facial and vestibulocochlear nerve emergence adjacent to the right tympanic bulla.

Note the presence of severe multifocal periodontal disease with a dental nasal fistula of the triadan 104.

**REFERRING VET**

Dr. Bogosian

**COMPUTED TOMOGRAPHIC DIAGNOSIS**

- Right sided retrobulbar abscess with extensive peripheral cellulitis, myositis, and exophthalmos. No evidence of foreign material seen.
- Moderate multiple regional lymphadenitis.
- Right sided otitis media and externa with intracranial extension and regional meningitis and/or neuritis (right facial and vestibulocochlear nerves).
- Severe multifocal periodontal disease with dental nasal fistula 104.

**INVOICE**

58839

**INTERPRETATION OF THE FINDINGS & FURTHER RECOMMENDATIONS**

**DATE**

6-14-23

The findings are compatible with an abscess within the right orbita with temporal and retromolar extension. Foreign material is not seen. However, small pieces of migrating organic foreign material cannot be ruled out. Extensive peripheral cellulitis, myositis, and lymphadenitis is noted. There also is right sided otitis externa and media with evidence of intracranial extension such as



**PATIENT**

reactive or infectious meningitis and/or neuritis.

Mitizi Obermiller

Abscess drainage is recommended. Conservative versus surgical management of the otitis media should be discussed. Note the presence of intracranial extension.

**SPECIES**

Dental workup should also be considered when reasonable.

Canine

**BREED**

Pug

**SEX**

Female Spayed

**AGE**

7

**INTERPRETED BY**

Nele Eley, DVM  
Dr. med. Vet. DipECVDI

**HOSPITAL NAME**

Animal Emergency  
Hospital Volusia

**REFERRING VET**

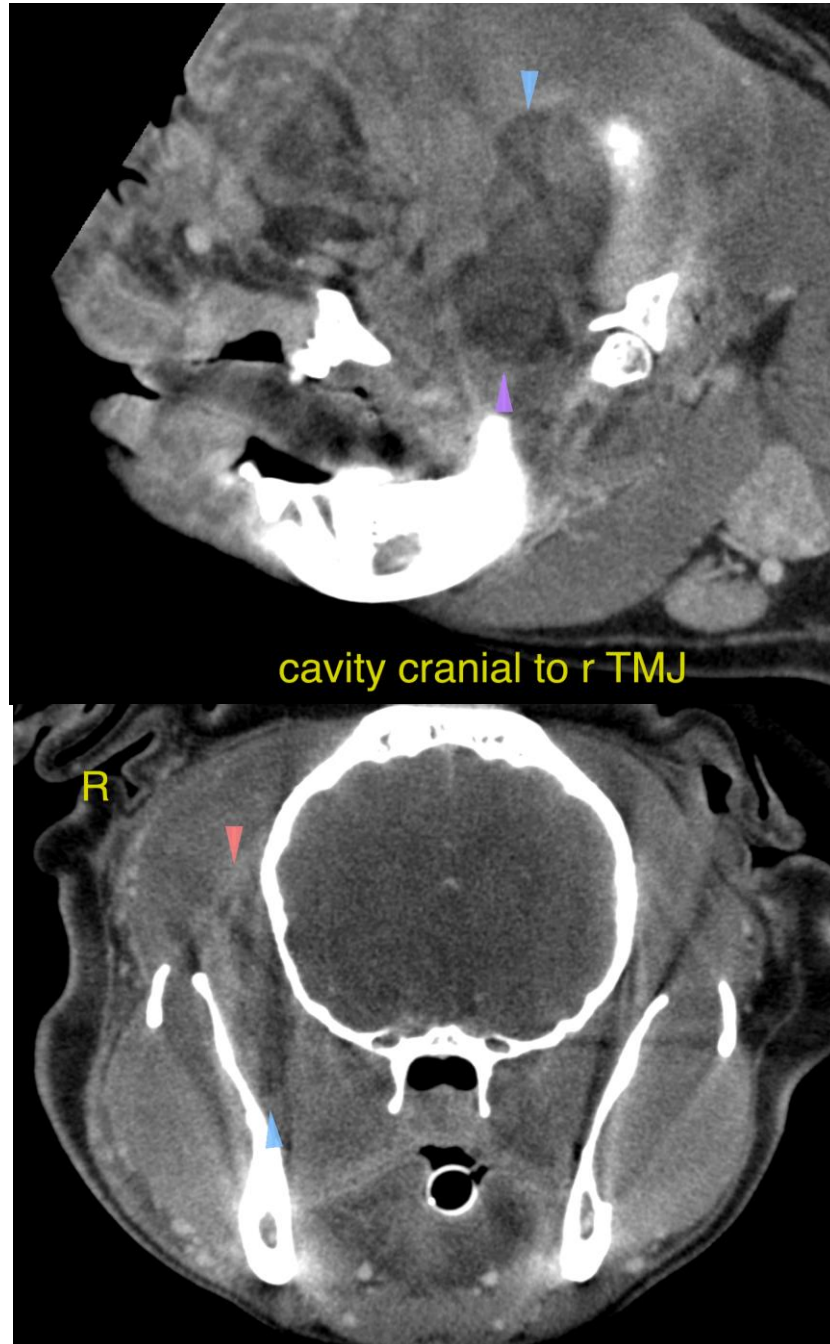
Dr. Bogosian

**INVOICE**

58839

**DATE**

6-14-23





**PATIENT**

Mitizi Obermiller

**SPECIES**

Canine

**BREED**

Pug

**SEX**

Female Spayed

**AGE**

7

**INTERPRETED BY**

Nele Eley, DVM  
Dr. med. Vet. DipECVDI

**HOSPITAL NAME**

Animal Emergency  
Hospital Volusia

**REFERRING VET**

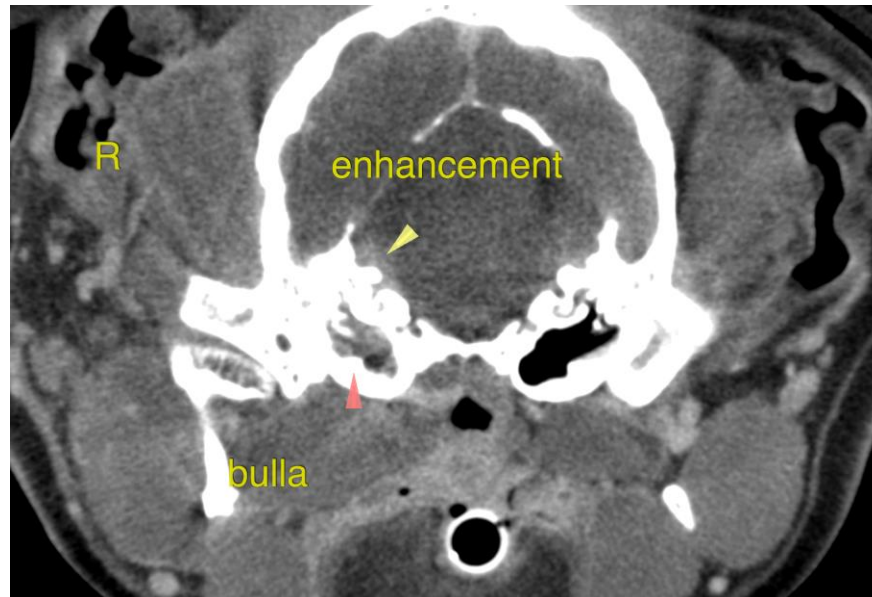
Dr. Bogosian

**INVOICE**

58839

**DATE**

6-14-23



The information and recommendations provided are based on the images presented by the referring veterinarian/sonographer. No evaluation can be communicated regarding pathology that was not visible in the image/video clips provided.

Thank you for this referral. If the clinical or image interpretation does not parallel your findings or if I can be of any further assistance please contact me.

**Nele Eley**, DVM, Dr. med. vet., DipECVDI  
European Specialist in Veterinary Diagnostic Imaging, Cert. Radiology,  
Senior lecturer University of Giessen, Germany, Veterinary Faculty, Department of Radiology  
[info@sonopath.com](mailto:info@sonopath.com)