



PATIENT PRESENTING CLINICAL SIGNS

Kitty Wiznura
 Mass Swelling emerging on the dorsal lateral left neck.
 Abnormal PE/Chem/CBC/UA Results: None

SPECIES ULTRASONOGRAPHIC FINDINGS

Feline **Upper Neck Musculature**

BREED

DSH

SEX

NM

Diffuse enlargement of the left capitis muscle with generalized increase in echogenicity is seen. The fascial planes are convex. A thin rim of anechoic signal is seen deep to the fascial planes within the muscle. The echoarchitecture of the musculature is obscured but still recognizable. The diffuse increase in echogenicity is accompanied by partial distal acoustic shadowing which precludes the delineation of the deep fascial planes. The muscle bundles appear to be separated by hypoechoic signal resulting in diffuse “cobblestone” appearance/inflammatory pattern. The underlying bones (left wing of the atlas) present no evidence of osteolytic or osteoproliferative changes as far as visible ultrasonographically. Deviation of the overlying fascial planes is noted due to the mass effect. The surrounding musculature presents within normal limits.

The lesion is neither associated with the thyroid gland nor with the retropharyngeal lymph nodes.

AGE

12

ULTRASONOGRAPHIC DIAGNOSIS

- Diffuse left capitis myopathy with mass effect, increased echogenicity, altered quality of the muscle fibers, and partial loss of echoarchitecture.

INTERPRETED BY

Nele Eley, DVM
 Dr. med. Vet. DipECVDI

INTERPRETATION OF THE FINDINGS & FURTHER RECOMMENDATIONS

The ultrasonographic study reveals diffuse myopathy of the left capitis muscle with increased volume, partial loss of echoarchitecture, “inflammatory pattern”, and increase in echogenicity. Inflammatory myopathy such as after perforating injury or migrating foreign material is a primary differential diagnosis. Muscular neoplasia such as rhabdomyosarcoma or other mesenchymal neoplasia and compartment syndrome cannot be ruled out entirely but are considered less likely based on the ultrasonographic appearance. Tissue biopsies are strongly recommended for further definition and cross sectional imaging could be considered depending on the results of the sampling in order to delineate the extent of the disease fully and navigate potential therapeutic procedures as well as to rule out regional lymph node involvement.

HOSPITAL NAME

FVS Imaging

REFERRING VET

Camerson Friesen

INVOICE

58853

DATE

6-14-23



PATIENT

Kitty Wiznura

SPECIES

Feline

BREED

DSH

SEX

NM

AGE

12

INTERPRETED BY

Nele Eley, DVM
Dr. med. Vet. DipECVDI

HOSPITAL NAME

FVS Imaging

REFERRING VET

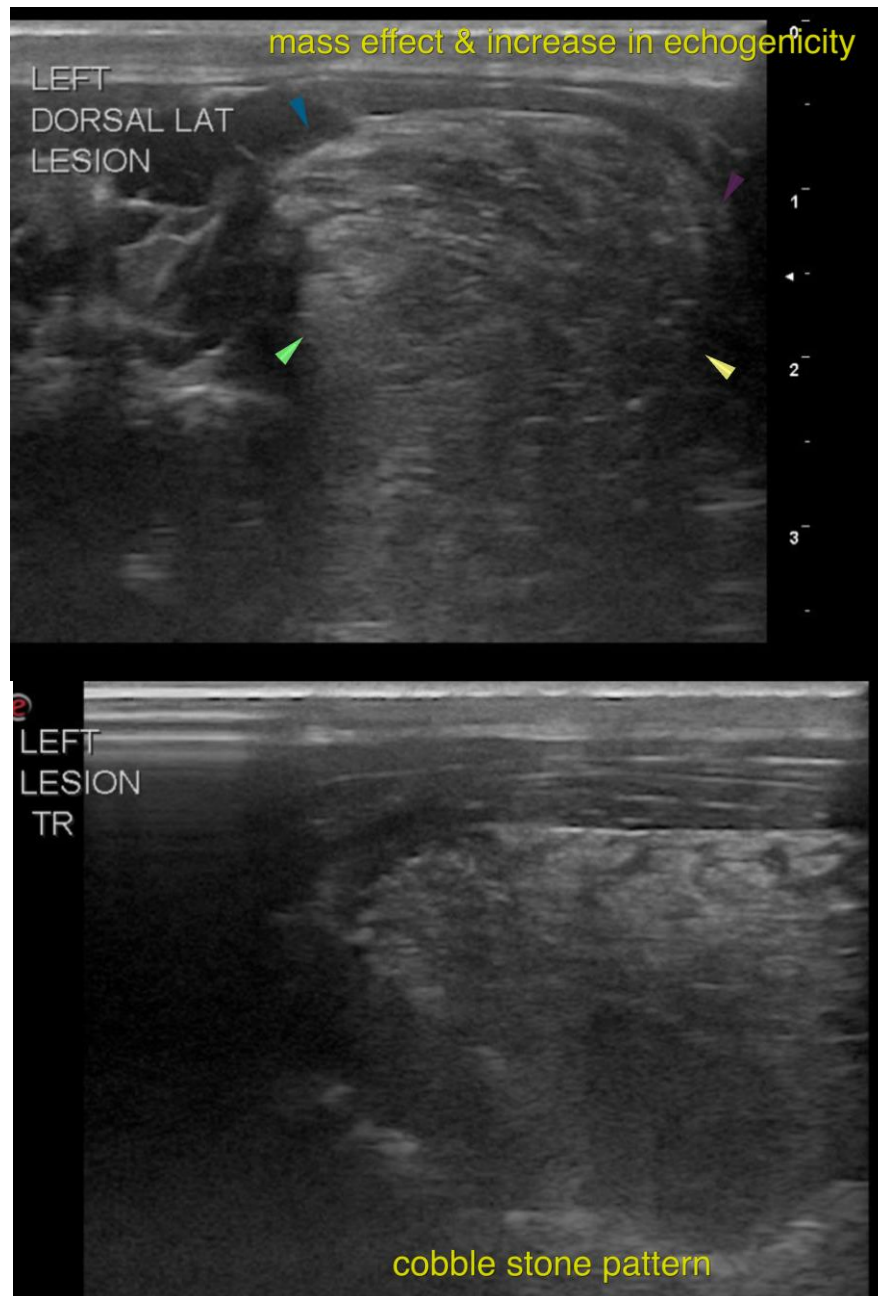
Camerson Friesen

INVOICE

58853

DATE

6-14-23





PATIENT

Kitty Wiznura

The information and recommendations provided are based on the images presented by the referring veterinarian/sonographer. No evaluation can be communicated regarding pathology that was not visible in the image/video clips provided.

Thank you for this referral. If the clinical or image interpretation does not parallel your findings or if I can be of any further assistance please contact me.

SPECIES

Feline

Nele Eley, DVM, Dr. med. vet., DipECVDI
European Specialist in Veterinary Diagnostic Imaging, Cert. Radiology,
Senior lecturer University of Giessen, Germany, Veterinary Faculty, Department of Radiology
info@sonopath.com

BREED

DSH

SEX

NM

AGE

12

INTERPRETED BY

Nele Eley, DVM
Dr. med. Vet. DipECVDI

HOSPITAL NAME

FVS Imaging

REFERRING VET

Camerson Friesen

INVOICE

58853

DATE

6-14-23