



PATIENT

Lola Borrero

PRESENTING CLINICAL SIGNS

The owner has the following concerns: patient was seen at tristate for a dental procedure. Patient aspirated during the procedure and has been having nasal discharge and coughs up white phlegm every so often

SPECIES

Canine

Abnormal PE/Chem/CBC/UA Results: PE: 2x2cm subcutaneous mass on the right ventral flank, Decreased airflow through the nose, Hard time breathing when mouth is closed CBC: Eosinophils 1.83 K/ μ L Chem: ALP 362 U/L

BREED

Doberman Pinscher

COMPUTED TOMOGRAPHIC STUDY OF THE HEAD, NECK, & THORAX

Plain and post contrast studies of the head and neck and plain study of the thorax available for review.

SEX

Female

Thorax

A mixed interstitial alveolar infiltrate is seen in the right middle and left cranial lung lobes. The changes are more pronounced in the right middle lobe with ventral accentuation. Pulmonary volume is maintained. Honeycombing and diffuse increase in interstitial and alveolar density is seen multifocally. Occasional condensing to miliary nodules is noted. The remainder of the lung presents within normal limits. Mild thickening of the bronchial walls of the right middle and left cranial lung lobes is seen as well.

AGE

9 Years, 5 Months, 16 Days

The mediastinal lymph nodes present within normal limits.

INTERPRETED BY

Nele Eley, DVM
Dr. med. Vet. DipECVDI

Multiple severe spondyloses are seen throughout the thoracic and lumbar spine.

Head & Neck

HOSPITAL NAME

Catskill Veterinary Services, PLLC

Extensive turbinate destruction is seen within the right nasal cavity. A moderate amount of fluid is accumulating in the caudal aspect of the right nasal cavity and nasal fundus.

The frontal sinuses present within normal limits. No foreign material and no soft tissue mass is seen.

REFERRING VET

Joseph D'Abbraccio, DVM

There is no evidence of relevant dental changes.

The right medial retropharyngeal lymph node is minimally enlarged.

Mild generalized swelling of the laryngeal soft tissues is seen.

Mild tracheal fluid accumulation is noted.

INVOICE

58808

The patient is intubated.

Both lobes of the thyroid gland present within normal limits.

DATE

6-13-23

Caudal cervical spondylomyelopathy with mild pointing of the dorsal aspect of the cranial endplate of C7 is seen.



PATIENT

Lola Borrero

SPECIES

Canine

BREED

Doberman Pinscher

SEX

Female

AGE

9 Years, 5 Months, 16
Days

INTERPRETED BY

Nele Eley, DVM
Dr. med. Vet. DipECVDI

HOSPITAL NAME

Catskill Veterinary
Services, PLLC

REFERRING VET

Joseph D'Abbraccio,
DVM

INVOICE

58808

DATE

6-13-23

COMPUTED TOMOGRAPHIC DIAGNOSIS

- Mixed pulmonary infiltrate with maintained pulmonary volume within the right middle and left cranial lung lobes.
- Mild tracheal fluid accumulation.
- Mild laryngeal swelling.
- Chronic destructive right hand sided rhinitis with fluid accumulation within the nasal fundus.
- Mild right medial retropharyngeal lymphadenomegaly.

INTERPRETATION OF THE FINDINGS & FURTHER RECOMMENDATIONS

The CT study reveals a mixed infiltrate in the right middle and left cranial lung lobes. Pneumonia such as aspiration pneumonia and less likely infectious pneumonia is considered most likely. The miliary consolidations are likely to represent pneumonic nodules.

The findings of the nasal cavity are compatible with unilateral right hand sided destructive rhinitis. Unilateral aspergillosis or other fungal infection is a primary differential diagnosis. Chronic bacterial rhinitis and rhinitis after foreign body related turbinate necrosis (or prior radiative treatment) are potential but less likely differential diagnoses.

The findings of the larynx and trachea suggest presence of edema in conjunction with the intubation or laryngotracheitis.

The right medial retropharyngeal lymphadenomegaly is very mild and compatible with reactive lymphadenitis.

Further definition by means of upper and lower airway endoscopy with sampling is recommended if not performed already.



PATIENT

Lola Borrero

SPECIES

Canine

BREED

Doberman Pinscher

SEX

Female

AGE

9 Years, 5 Months, 16 Days

INTERPRETED BY

Nele Eley, DVM
Dr. med. Vet. DipECVDI

HOSPITAL NAME

Catskill Veterinary Services, PLLC

REFERRING VET

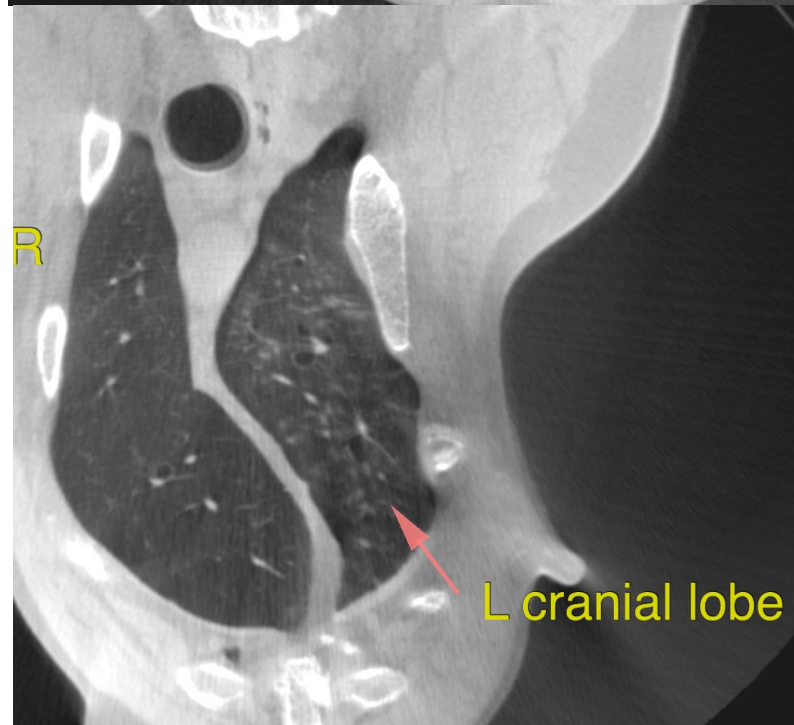
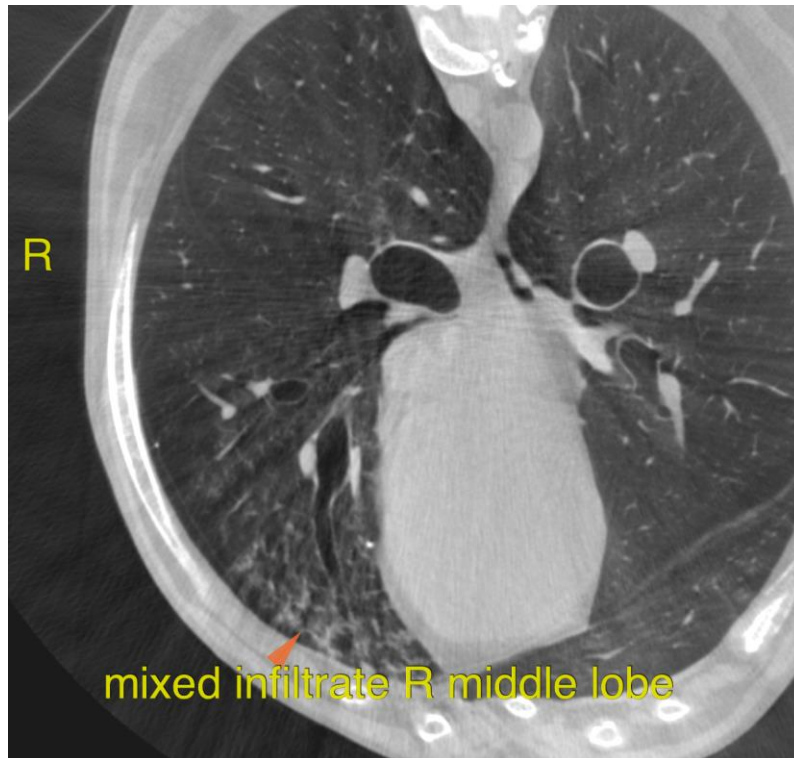Joseph D'Abbraccio, DVM

INVOICE

58808

DATE

6-13-23





PATIENT

Lola Borrero

SPECIES

Canine

BREED

Doberman Pinscher

SEX

Female

AGE

9 Years, 5 Months, 16 Days

INTERPRETED BY

Nele Eley, DVM
Dr. med. Vet. DipECVDI

HOSPITAL NAME

Catskill Veterinary Services, PLLC

REFERRING VET

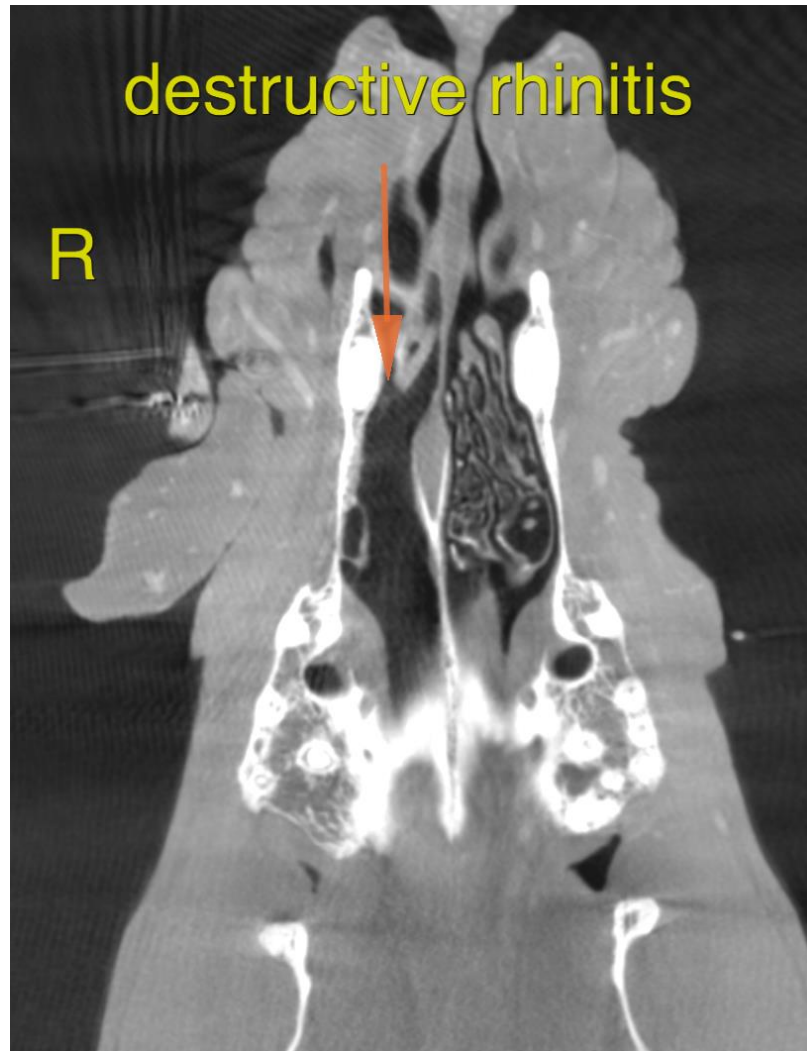
Joseph D'Abbraccio, DVM

INVOICE

58808

DATE

6-13-23



The information and recommendations provided are based on the images presented by the referring veterinarian/sonographer. No evaluation can be communicated regarding pathology that was not visible in the image/video clips provided.

Thank you for this referral. If the clinical or image interpretation does not parallel your findings or if I can be of any further assistance please contact me.

Nele Eley, DVM, Dr. med. vet., DipECVDI
European Specialist in Veterinary Diagnostic Imaging, Cert. Radiology,
Senior lecturer University of Giessen, Germany, Veterinary Faculty, Department of Radiology
info@sonopath.com