



PATIENT

Breigh Jackson

PRESENTING CLINICAL SIGNS

Has had bilateral CCL damage for over a year. Had TTA on the left knee Aug 2022, Today TTA on the right knee.

SPECIES

Canine

Abnormal PE/Chem/CBC/UA Results: Positive Cranial drawer sign, positive CTT, Large medial buttress. Joint has crepitus, some restriction to full hyperextension. Decreased muscle mass on this leg.

ULTRASONOGRAPHIC FINDINGS

BREED

Lab Mix

Right Stifle

A large amount of effusion is seen in the supra- and infra-patellar recesses of the right stifle joint. Extensive thickening of the synovium and capsular fibrosis are noted. A large amount of periarticular osteophytes is seen. Significant heterogeneity of the infrapatellar fat pad is noted. The visible cartilage surfaces present within normal limits. The cruciate ligament presents as a short stump of heterogeneous appearance at the intercondylar eminence of the tibia. Internal heterogeneity of the lateral and medial menisci is seen with no evidence of intersecting full thickness defects and no evidence of displacement. Moderate thickening of the medial collateral ligament is noted.

SEX

FS

AGE

8 Years, 1 Month

ULTRASONOGRAPHIC DIAGNOSIS

- Severe osteoarthritis of the right stifle joint with synovialitis, capsular fibrosis, effusion, and osteophytosis.
- Full rupture of the right cranial cruciate ligament.
- Echogenicity changes of the in situ lateral and medial menisci suggesting presence of internal degenerative changes.

INTERPRETED BY

Nele Eley, DVM
Dr. med. Vet. DipECVDI

INTERPRETATION OF THE FINDINGS & FURTHER RECOMMENDATIONS

The ultrasonographic study confirms presence of a full rupture of the right cranial cruciate ligament. Severe concurrent osteoarthritic changes are seen. The internal echogenicity changes of the lateral and medial menisci suggest presence of degenerative changes of the menisci. At this time, there is no ultrasonographic evidence of meniscal tearing, rupture, or displacement.

HOSPITAL NAME

Westview Veterinary
Hospital

REFERRING VET

Dr. Brian Barnes

INVOICE

58787

DATE

6-13-23



PATIENT

Breigh Jackson

SPECIES

Canine

BREED

Lab Mix

SEX

FS

AGE

8 Years, 1 Month

INTERPRETED BY

Nele Eley, DVM
Dr. med. Vet. DipECVDI

HOSPITAL NAME

Westview Veterinary
Hospital

REFERRING VET

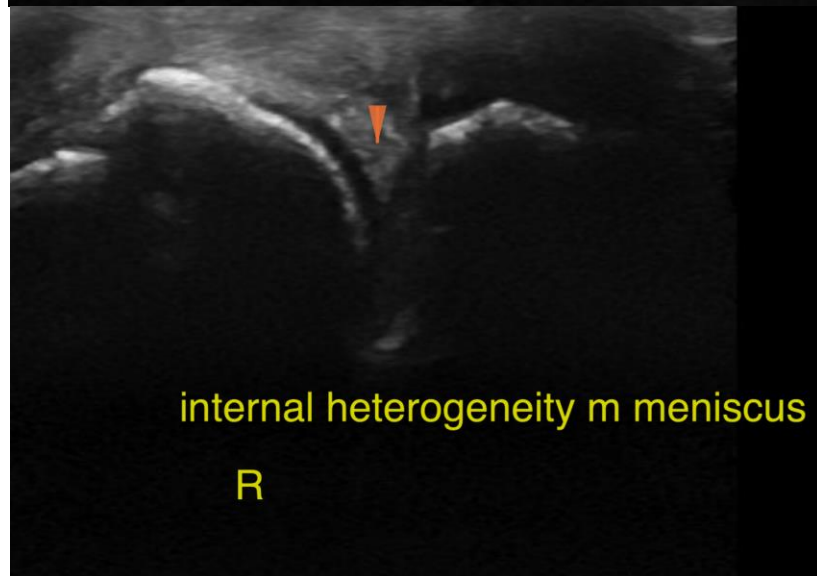
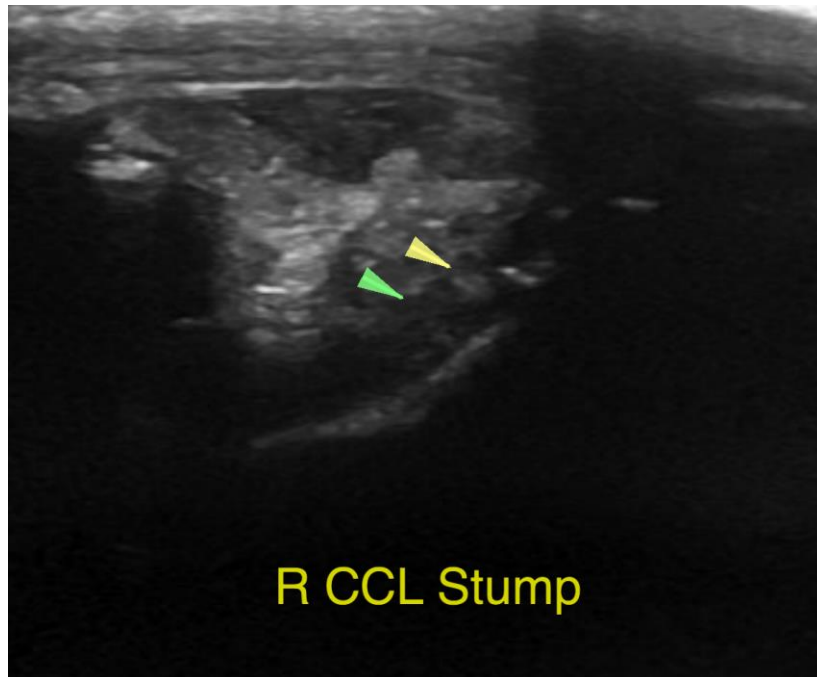
Dr. Brian Barnes

INVOICE

58787

DATE

6-13-23





PATIENT

Breigh Jackson

The information and recommendations provided are based on the images presented by the referring veterinarian/sonographer. No evaluation can be communicated regarding pathology that was not visible in the image/video clips provided.

Thank you for this referral. If the clinical or image interpretation does not parallel your findings or if I can be of any further assistance please contact me.

SPECIES

Canine

Nele Eley, DVM, Dr. med. vet., DipECVDI
European Specialist in Veterinary Diagnostic Imaging, Cert. Radiology,
Senior lecturer University of Giessen, Germany, Veterinary Faculty, Department of Radiology
info@sonopath.com

BREED

Lab Mix

SEX

FS

AGE

8 Years, 1 Month

INTERPRETED BY

Nele Eley, DVM
Dr. med. Vet. DipECVDI

HOSPITAL NAME

Westview Veterinary
Hospital

REFERRING VET

Dr. Brian Barnes

INVOICE

58787

DATE

6-13-23