



PATIENT PRESENTING CLINICAL SIGNS

Rollins Igel
 On May 29th, had a nose bleed from R nostril that wouldn't stop and went to an ER. He has a history of low total WBC (~3K) and low end of the range platelets (~120K) over many different blood draws. He's been tested twice for tick borne diseases and was negative both times. Blood chemistry normal.

SPECIES

Canine

Abnormal PE/Chem/CBC/UA Results: He has a history of low total WBC (~3K) and low end of the range platelets (~120K) over many different blood draws. He's been tested twice for tick borne diseases and was negative both times. Blood chemistries normal.

BREED

Lab Retriever Mix

COMPUTED TOMOGRAPHIC STUDY OF THE HEAD

Plain and post contrast studies available for review.

COMPUTED TOMOGRAPHIC FINDINGS

SEX

MN

The CT study reveals minimal focal mucosal swelling within the nasal cavities. No evidence of turbinate destruction is noted. No significant fluid accumulation is seen within the nasal cavities or paranasal sinuses. There is no evidence of foreign material. A minimal amount of fluid is present within the left nare. No soft tissue mass is seen.

AGE

5 Years

The brain presents no deviation from normal anatomy and symmetry. The grey and white matter distinction and the neuroparenchymal attenuation are as expected. The distribution of contrast enhancement is within normal limits throughout the parenchyma and meninges. The ventricular system is non-dilated and within the limits of the expected volume and symmetry.

INTERPRETED BY

Nele Eley, DVM
 Dr. med. Vet. DipECVDI

Both temporomandibular joints present congruent joint spaces with even subchondral bone surfaces and are considered within normal limits.

Both tympanic bullae are aerated, the mucosal lining is not seen, the bony wall is smooth and thin. The external auditory meatuses present within normal limits.

HOSPITAL NAME

Animal Health Care
 Denver

Mild symmetric enlargement of the bilateral medial retropharyngeal lymph nodes is seen.

The salivary glands present within normal limits.

The triadan 201 is absent. The remainder of the dentition presents within normal limits.

REFERRING VET

Cathryn Sayer

COMPUTED TOMOGRAPHIC DIAGNOSIS

- Minimal focal mucosal swelling within the bilateral nasal cavities - otherwise normal CT presentation of the nasal cavities and paranasal sinuses.
- Mild bilaterally symmetric retropharyngeal lymphadenomegaly.

INVOICE

58795

INTERPRETATION OF THE FINDINGS & FURTHER RECOMMENDATIONS

DATE

6-12-23

Minimal focal mucosal swelling is seen within the bilateral nasal cavities and is of uncertain clinical significance. No significant signs supporting the presence of destructive or nondestructive rhinitis, no foreign material, no relevant dental disease, and no soft tissue mass is seen. Consider systemic hypertension, coagulopathy, and paraneoplastic syndrome as potential differential diagnoses next to mild nondestructive rhinitis which can be infectious such as viral,



PATIENT

bacterial, or noninfectious such as irritant rhinitis, lymphoplasmacytic, or allergic rhinitis.

Rollins Igel

The mild enlargement of the retropharyngeal lymph nodes is compatible with reactive hyperplasia. Lymphomatous or other neoplastic infiltrate is considered unlikely but can never be ruled out entirely. FNA is recommended for further definition.

SPECIES

Canine

BREED

Lab Retriever Mix

SEX

MN

AGE

5 Years

INTERPRETED BY

Nele Eley, DVM
Dr. med. Vet. DipECVDI

HOSPITAL NAME

Animal Health Care
Denver

REFERRING VET

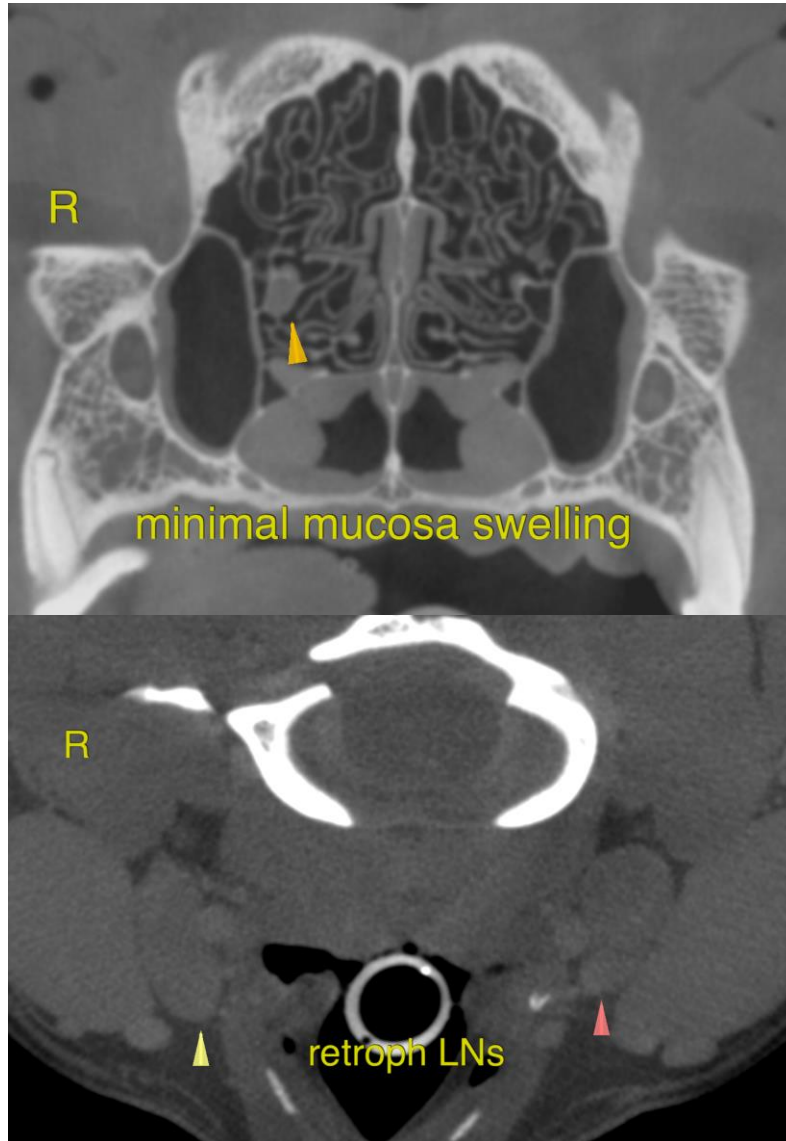
Cathryn Sayer

INVOICE

58795

DATE

6-12-23





PATIENT

Rollins Igel

The information and recommendations provided are based on the images presented by the referring veterinarian/sonographer. No evaluation can be communicated regarding pathology that was not visible in the image/video clips provided.

Thank you for this referral. If the clinical or image interpretation does not parallel your findings or if I can be of any further assistance please contact me.

SPECIES

Canine

Nele Eley, DVM, Dr. med. vet., DipECVDI
European Specialist in Veterinary Diagnostic Imaging, Cert. Radiology,
Senior lecturer University of Giessen, Germany, Veterinary Faculty, Department of Radiology
info@sonopath.com

BREED

Lab Retriever Mix

SEX

MN

AGE

5 Years

INTERPRETED BY

Nele Eley, DVM
Dr. med. Vet. DipECVDI

HOSPITAL NAME

Animal Health Care
Denver

REFERRING VET

Cathryn Sayer

INVOICE

58795

DATE

6-12-23