



PATIENT

Tyson Bolger

PRESENTING CLINICAL SIGNS

Lethargic and lacking energy over the last two days, trouble bearing weight on back legs, balance issues. Not eating or drinking well. Very pale gum colour
 Abnormal PE/Chem/CBC/UA Results: Blood work shows low platelets, high liver values, non-regenerative anemia with an unknown cause. B/W attached

SPECIES

Canine

RADIOGRAPHIC STUDY OF THE ABDOMEN

Right/left lateral and ventrodorsal views totaling 5 images available for review.

BREED

Poodle Mix

RADIOGRAPHIC FINDINGS

The abdominal cavity is voluminous with pendulous ventral abdominal wall.

SEX

Male

The abdominal serosal detail is reduced in the cranial and ventral abdomen.

Severe mass like enlargement of the liver is noted accentuating the cranial division. The caudal contour of the liver is rounded and irregular. There is severe dorsal displacement of the post-prandial stomach.

AGE

13 Years

The splenic head and tail appear to be small, and volume contracted.

The caudal vena cava and pulmonary vasculature are thin.

INTERPRETED BY

Nele Eley, DVM
 Dr. med. Vet. DipECVDI

RADIOGRAPHIC DIAGNOSIS

- Mass like enlargement of the liver with gastric deviation and compression.
- Regional peritoneal effusion.

HOSPITAL NAME

Truscott Animal Hospital

INTERPRETATION OF THE FINDINGS & FURTHER RECOMMENDATIONS

The radiographic study reveals mass like enlargement of the liver. Consider neoplasia, abscess, hematoma, and less likely granuloma or cyst potential differential diagnoses. There appears to be a mild amount of regional peritoneal effusion which may represent hemorrhage, paraneoplastic effusion, peritonitis, and less likely transudate due to compression of the caudal vena cava and increased intraabdominal pressure. Further definition by means of ultrasound or CT with eventual sampling is recommended in order to obtain more detailed information on the prognosis and potential resectability as well as staging.

REFERRING VET

Dr. Medhat Meawad

INVOICE

52233

DATE

6-1-22



PATIENT

Tyson Bolger

SPECIES

Canine

BREED

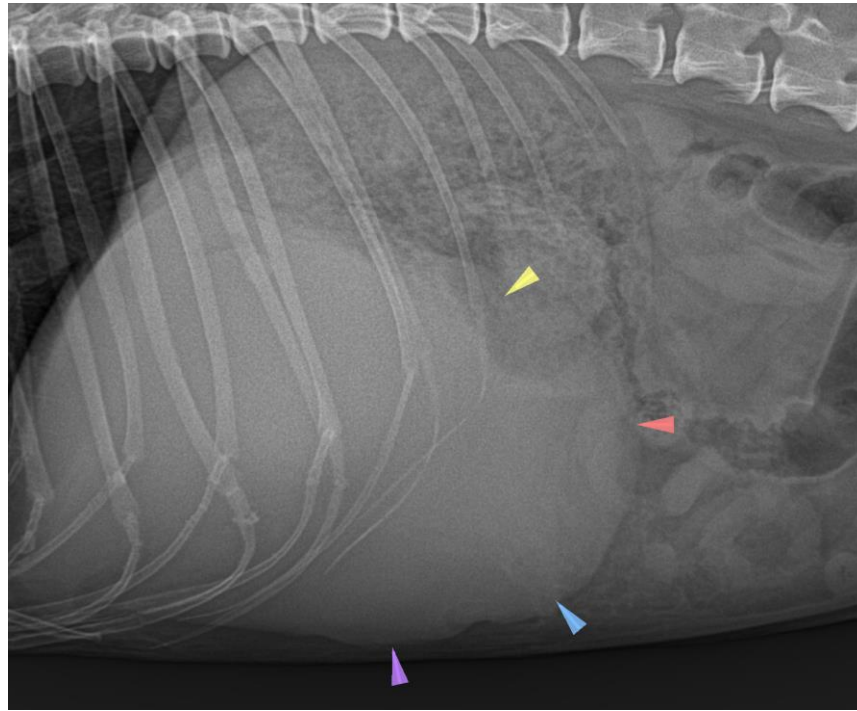
Poodle Mix

SEX

Male

AGE

13 Years



INTERPRETED BY

Nele Eley, DVM
Dr. med. Vet. DipECVDI

The information and recommendations provided are based on the images presented by the referring veterinarian/sonographer. No evaluation can be communicated regarding pathology that was not visible in the image/video clips provided.

Thank you for this referral. If the clinical or image interpretation does not parallel your findings or if I can be of any further assistance please contact me.

HOSPITAL NAME

Truscott Animal
Hospital

Nele Eley, DVM, Dr. med. vet., DipECVDI
European Specialist in Veterinary Diagnostic Imaging, Cert. Radiology,
Senior lecturer University of Giessen, Germany, Veterinary Faculty, Department of Radiology
Nele.Eley@sonopath.com

REFERRING VET

Dr. Medhat Meawad

INVOICE

52233

DATE

6-1-22