



PATIENT

Tylan Giuliani

PRESENTING CLINICAL SIGNS

Hx of asthma, controlled with prednisolone every other day. Occasionally wheezing, no coughing. Attached previous chest xrays from 9-7-21 for comparison.

SPECIES

Feline

RADIOGRAPHIC STUDY OF THE THORAX

Right/left lateral and dorsoventral views totaling 3 images available for review in Dicom format. Three-view study dated 7-21 available for comparison in jpeg format.

BREED

DSH

RADIOGRAPHIC FINDINGS

The vertebral heart score is 8 and stationary.

SEX

NM

The lungs are moderately inflated. A moderate generalized bronchial lung pattern with mild peribronchial cuffing is noted with slight caudodorsal accentuation. However, the findings are distributed throughout the entire lung.

AGE

6 Years

No evidence of mediastinal lymphadenomegaly is seen.

Course and width of the trachea are considered within normal limits.

RADIOGRAPHIC DIAGNOSIS

- Stationary moderate active bronchial lung pattern.

INTERPRETED BY

Nele Eley, DVM
Dr. med. Vet. DipECVDI

INTERPRETATION OF THE FINDINGS & FURTHER RECOMMENDATIONS

The radiographic findings are compatible with the history of allergic lower airway syndrome. At this time, the findings are considered stationary compared with the prior study. Moderate signs of lower airway disease are seen radiographically. The degree of air trapping appears to be minor at this point.

HOSPITAL NAME

The Pet Hospital of
Stratford

REFERRING VET

Dr. Claudia Giuliani

INVOICE

52247

DATE

6-1-22



PATIENT

Tylan Giuliani

SPECIES

Feline

BREED

DSH

SEX

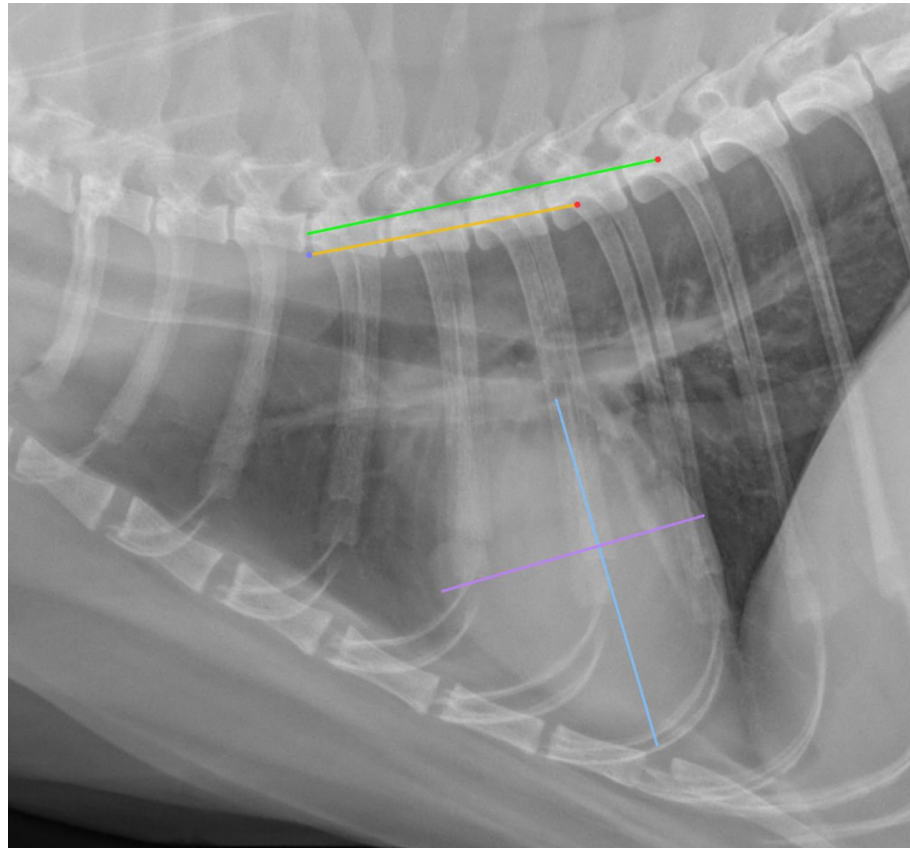
NM

AGE

6 Years

INTERPRETED BY

Nele Eley, DVM
Dr. med. Vet. DipECVDI



HOSPITAL NAME

The Pet Hospital of
Stratford

REFERRING VET

Dr. Claudia Giuliani

INVOICE

52247

DATE

6-1-22

The information and recommendations provided are based on the images presented by the referring veterinarian/sonographer. No evaluation can be communicated regarding pathology that was not visible in the image/video clips provided.

Thank you for this referral. If the clinical or image interpretation does not parallel your findings or if I can be of any further assistance please contact me.

Nele Eley, DVM, Dr. med. vet., DipECVDI
European Specialist in Veterinary Diagnostic Imaging, Cert. Radiology,
Senior lecturer University of Giessen, Germany, Veterinary Faculty, Department of Radiology
Nele.Eley@sonopath.com