



PATIENT PRESENTING CLINICAL SIGNS

Dice Celebi Panting excessively and as per O last few days panting excessively during the night and not sleeping. No heart murmur on auscultation, normal chest sound, no wheeze or crackles. B/W WNL

SPECIES Abnormal PE/Chem/CBC/UA Results: See attached B/W

Canine **RADIOGRAPHIC STUDY OF THE THORAX**

Right/left lateral and ventrodorsal views of the thorax totaling 6 images available for review.

BREED RADIOGRAPHIC FINDINGS

English Bulldog Moderate right sided cardiomegaly with rounded right ventricle and increased sternal contact is seen. The vertebral heart score is 12.5. The caudal vena cava is not dilated. There appears to be enlargement of the pulmonary artery indicated on the orthogonal view as well by a subtle hat sign on the lateral view.

SEX Male The lung presents a mild to moderate bronchial lung pattern accentuated in the caudodorsal aspect of the lung. The impression of a bronchial lung pattern is diminished on the better inflated views. There is no obvious evidence of a vascular lung pattern. Occasional pulmonary osteomas are seen.

AGE 12 Years Mild to moderate spondyloses are present within the thoracic spine.

INTERPRETED BY There is no evidence of hepatomegaly.

Nele Eley, DVM
Dr. med. Vet. DipECVDI

RADIOGRAPHIC DIAGNOSIS

- Moderate right sided cardiomegaly.
- Suspect pulmonary arterial enlargement.
- Mild caudodorsal bronchial lung pattern.
- Spondyloses.

HOSPITAL NAME

Truscott Animal Hospital

INTERPRETATION OF THE FINDINGS & FURTHER RECOMMENDATIONS

The radiographic study reveals significant right sided cardiomegaly. There also is the impression of main pulmonary artery enlargement. Consider pulmonic stenosis, cor pulmonale, and less likely tricuspid valve disease a potential in this patient. Further definition by means of a full cardiac echo is recommended if not performed already.

REFERRING VET

Dr. Medhat Meawad

INVOICE The bronchial lung pattern is relatively mild; however, lower airway disease such as infectious bronchitis including parasitic such as lung or heartworm and allergic/eosinophilic bronchopneumopathy cannot be ruled out.

52280

DATE

6-1-22



PATIENT

Dice Celebi

SPECIES

Canine

BREED

English Bulldog

SEX

Male

AGE

12 Years

INTERPRETED BY

Nele Eley, DVM
Dr. med. Vet. DipECVDI

HOSPITAL NAME

Truscott Animal
Hospital

REFERRING VET

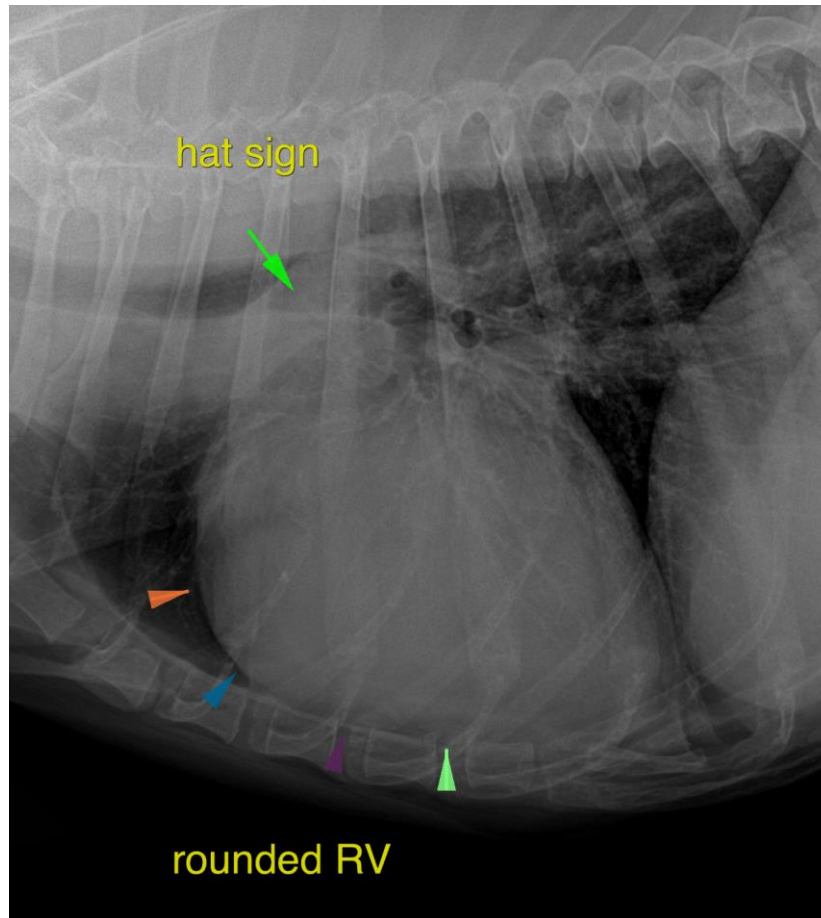
Dr. Medhat Meawad

INVOICE

52280

DATE

6-1-22



The information and recommendations provided are based on the images presented by the referring veterinarian/sonographer. No evaluation can be communicated regarding pathology that was not visible in the image/video clips provided.

Thank you for this referral. If the clinical or image interpretation does not parallel your findings or if I can be of any further assistance please contact me.

Nele Eley, DVM, Dr. med. vet., DipECVDI
European Specialist in Veterinary Diagnostic Imaging, Cert. Radiology,
Senior lecturer University of Giessen, Germany, Veterinary Faculty, Department of Radiology
Nele.Eley@sonopath.com