



PATIENT

Minnow Scully

SPECIES

Canine

BREED

Chi/Poo

SEX

FS

AGE

16Y

WEIGHT

13.5lbs

INTERPRETED BY

Nele Eley (Ondreka),
DVM Dr. med. vet.,
DipECVDF

IMAGING PERFORMED BY

Dr. Amanda Causey

HOSPITAL NAME

Island Animal Hospital

REFERRING VET

Dr. Scully

INVOICE

74940

DATE

5-9-26

PRESENTING CLINICAL SIGNS

Dr. Scully noted abnormal retropulsion. Concerned for orbital mass.

COMPUTED TOMOGRAPHIC STUDY OF THE HEAD

Plain and post contrast studies are available for review.

COMPUTED TOMOGRAPHIC FINDINGS

An irregular shaped soft tissue mass measuring approximately 10 x 10 x 15mm is identified in the dorsal temporal region of the right orbita located caudodorsal and lateral to the globe. The lesion demonstrates nonuniform contrast enhancement. Lesion margins are ill-defined; however, the lesion appears to be distinct from the globe itself with no direct intraocular invasion being identified. There is a mild mass effect onto adjacent soft tissues consistent with a space occupying lesion. The globe remains structurally intact and appropriately positioned although clinical retropulsion findings are supported by the regional mass effect. The lesion appears accessible for sampling based on its superficial and lateral/temporal location. No aggressive bone lysis or proliferation is noted in the surrounding skull or orbital bones.

The regional lymph nodes are within normal size and attenuation limits with no overt evidence of regional metastatic disease.

A persistent fontanelle is noted consistent with congenital variation.

Mild periodontal disease is present multifocally.

Mild generalized enlargement of the left zygomatic gland with possible mild mass effect within the left orbit and associated mild exophthalmos. No focal tissue alteration, cystic change, mass lesion, or other structural abnormality is evident within the gland on the current study.

COMPUTED TOMOGRAPHIC DIAGNOSIS

- Right dorsal temporal soft tissue mass.
- No evidence of regional lymphadenopathy.
- Possible enlargement left zygomatic gland.

INTERPRETATION OF FINDINGS & FURTHER RECOMMENDATIONS

The CT study reveals a right orbital soft tissue mass in a dorsal temporal position. Differential diagnosis includes soft tissue neoplasia, which is considered most likely such as mast cell tumor, soft tissue sarcoma, sebaceous adenocarcinoma, and less likely benign mass such as granuloma, lacrimal gland hyperplasia, inflammatory or infectious lesion. There is no evidence of orbital invasion, bone destruction, or regional lymph node involvement. FNA or biopsy of the mass is strongly recommended for further definition if not performed already. Consider ophthalmologic assessment if not performed already. Surgical excision appears feasible based on the CT presentation. Staging, including FNA of the regional lymph nodes and thoracoabdominal imaging, could be considered depending on the results of cytology/histopathology.

The increased size of the left zygomatic gland may represent normal anatomical variation, although mild or early pathology (including inflammatory or other infiltrative processes) cannot be entirely excluded. Given the absence of definitive structural abnormalities, correlation with the clinical and ophthalmologic findings is recommended. Clinical and/or imaging follow-up may be considered if signs



PATIENT

Minnow Scully

SPECIES

Canine

BREED

Chi/Poo

SEX

FS

AGE

16Y

WEIGHT

13.5lbs

INTERPRETED BY

Nele Eley (Ondreka),
DVM Dr. med. vet.,
DipECVDI

IMAGING PERFORMED BY

Dr. Amanda Causey

HOSPITAL NAME

Island Animal Hospital

REFERRING VET

Dr. Scully

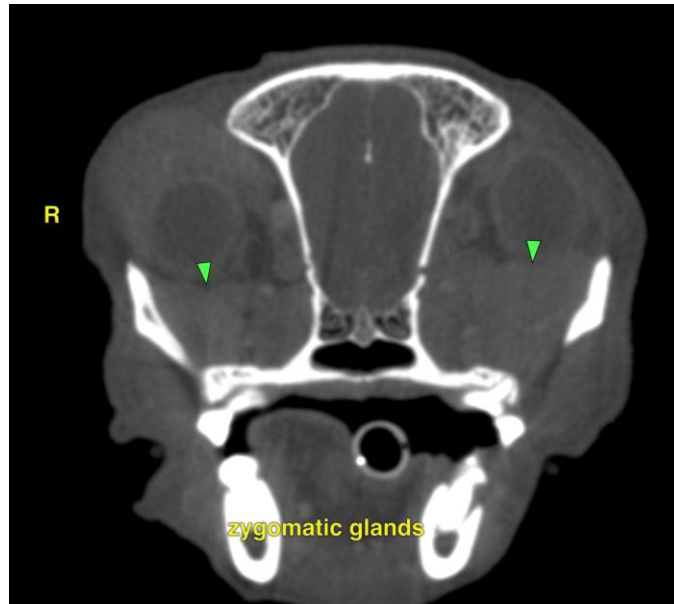
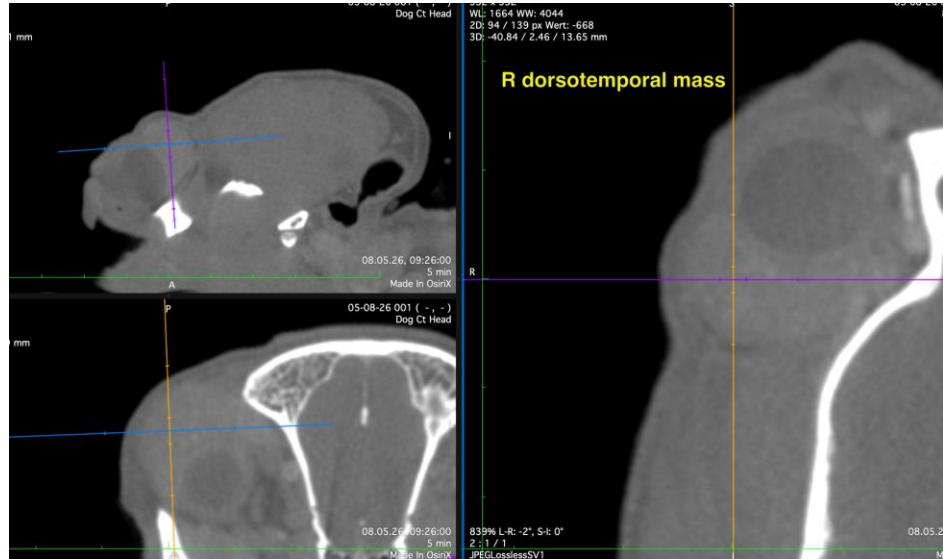
INVOICE

74940

DATE

5-9-26

persist or progress, and a complete ophthalmologic evaluation is advised if not already performed.



The information and recommendations provided are based on the images presented by the referring veterinarian. No evaluation can be communicated regarding pathology that was not visible in the image/video clips provided.

Thank you for this referral. If the clinical or image interpretation does not parallel your findings or if I can be of any further assistance please contact me.

Nele Eley (Ondreka), DVM, Dr. med. vet., DipECVDI
European Specialist in Veterinary Diagnostic Imaging, Cert. Radiology,
Senior lecturer University of Giessen/Germany, Veterinary Faculty, Department of Radiology.
info@sonopath.com