



**PATIENT PRESENTING CLINICAL SIGNS**

Trevor Gomez patient presented for evaluation of a mass on right distal jugular groove mass on ventral neck region it has been there for a few months. 2x2 cm mass movable mass originated from right distal jugular groove.

**SPECIES** Abnormal PE/Chem/CBC/UA Results: 4/18/23- cbc/chem AST (low) 13 Triglyceride (high) 333

Canine **COMPUTED TOMOGRAPHIC STUDY OF THE HEAD, NECK, & THORAX**

Post contrast studies available for review.

**BREED COMPUTED TOMOGRAPHIC FINDINGS**

Yorkshire Terrier

**Head & Neck**

Mass like enlargement of the right cervical lymph node measuring 3.5 x 3.0 cm is seen. Lymph node margins are ill-defined. The lymph node is rounded and presents heterogeneous contrast enhancement. The left cervical lymph node presents within normal limits.

**SEX**

Male Neutered

Collapse of the intervertebral disc space C6/7 with vertebral endplate sclerosis and spondylosis deformans is noted.

**AGE**

14 Years, 1 Month

The dentition presents hypodontia with multiple absent teeth. The remaining teeth present mild to moderate signs of periodontal disease and multifocal tooth root resorption. Multiple small proliferative changes of the epithelial lining of the external auditory meatuses is seen bilaterally.

**INTERPRETED BY**

Nele Eley, DVM  
Dr. med. Vet. DipECVDI

The submandibular and medial retropharyngeal lymph nodes present within normal limits.

Moderate collapse of the cervical trachea is seen.

**HOSPITAL NAME**

Animal Surgical  
Center

Both lobes of the thyroid gland are seen and present within normal limits.

**Thorax**

The intrathoracic trachea presents no evidence of collapse.

**REFERRING VET**

Astoria Veterinary  
Group

A mild generalized bronchointerstitial lung pattern is noted and considered within age related normal limits. No evidence of interstitial pulmonary nodules or masses is seen. There are occasional, peripheral, and subpleural interstitial bands. The caudal tip of the right caudal lung lobe is not fully included in the study.

The mediastinal lymph nodes present within normal limits.

**INVOICE COMPUTED TOMOGRAPHIC DIAGNOSIS**

58202

- Mass like enlargement of the right cervical lymph node meeting neoplastic criteria.
- Dynamic tracheal disease- likely secondary to bronchomalacia.
- Normal age related lung with no evidence of metastatic disease.
- Normal mediastinal, submandibular, and retropharyngeal lymph nodes.
- Hypodontia and periodontal disease.

**DATE**

5-9-23



**PATIENT**

Trevor Gomez

**SPECIES**

Canine

**BREED**

Yorkshire Terrier

**SEX**

Male Neutered

**AGE**

14 Years, 1 Month

**INTERPRETED BY**

Nele Eley, DVM  
Dr. med. Vet. DipECVDI

**HOSPITAL NAME**

Animal Surgical  
Center

**REFERRING VET**

Astoria Veterinary  
Group

**INVOICE**

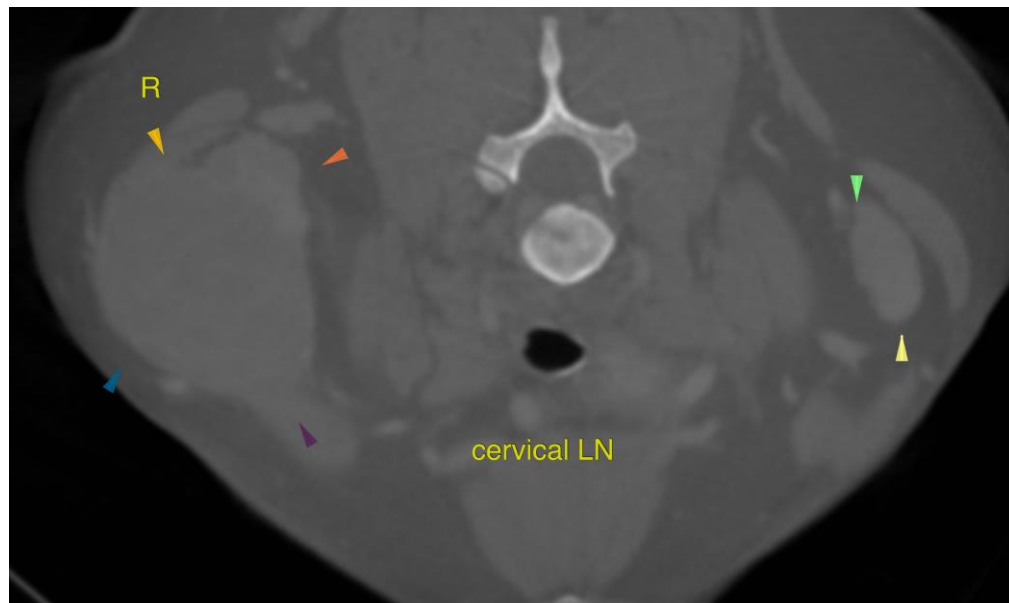
58202

**DATE**

5-9-23

**INTERPRETATION OF THE FINDINGS & FURTHER RECOMMENDATIONS**

The CT study reveals mass like expansile enlargement of the right cervical lymph node meeting neoplastic criteria. A primary lymphomatous infiltrate and metastatic disease of undetermined primary tumor are primary differential diagnoses. Final diagnosis will require sampling for cytology or histology.



The information and recommendations provided are based on the images presented by the referring veterinarian/sonographer. No evaluation can be communicated regarding pathology that was not visible in the image/video clips provided.

Thank you for this referral. If the clinical or image interpretation does not parallel your findings or if I can be of any further assistance please contact me.

Nele Eley, DVM, Dr. med. vet., DipECVDI  
European Specialist in Veterinary Diagnostic Imaging, Cert. Radiology,  
Senior lecturer University of Giessen, Germany, Veterinary Faculty, Department of Radiology  
Nele.Eley@sonopath.com