



PATIENT

Raven Brayley

PRESENTING CLINICAL SIGNS

coughing occasionally R/O hairball vs allergy vs others

SPECIES

Feline

RADIOGRAPHIC STUDY OF THE THORAX

Right/left lateral and ventrodorsal whole body views totaling 4 images available for review.

Thoracic read requested.

BREED

Domestic Shorthair

RADIOGRAPHIC FINDINGS

The lungs are deeply inflated. The ribcage is mildly expanded.

A moderate generalized bronchial lung pattern is noted and evenly distributed throughout the lung.

SEX

Female Spayed

No obvious cardiomegaly and no specific chamber enlargement is seen. The pulmonary vasculature presents within normal limits.

AGE

4 Years

There is no evidence of mediastinal widening.

Course and width of the trachea are considered within normal limits.

INTERPRETED BY

Nele Eley, DVM
Dr. med. Vet. DipECVDI

RADIOGRAPHIC DIAGNOSIS

- Lower airway pattern with air trapping.

INTERPRETATION OF THE FINDINGS & FURTHER RECOMMENDATIONS

The radiographic findings support the presence of chronic lower airway disease such as allergic lower airway syndrome. Infectious bronchitis such as viral, bacterial, parasitic, or protozoal is a theoretical but less likely differential diagnosis in this species. Consider a clinical trial of treatment for feline asthma. Airway endoscopy with airway sampling could be considered alternatively.

HOSPITAL NAME

Truscott Animal
Hospital

REFERRING VET

Medhat Meawad

INVOICE

52036

DATE

5-9-22



PATIENT

Raven Brayley

SPECIES

Feline

BREED

Domestic Shorthair

SEX

Female Spayed

AGE

4 Years

INTERPRETED BY

Nele Eley, DVM
Dr. med. Vet. DipECVDI

HOSPITAL NAME

Truscott Animal
Hospital

REFERRING VET

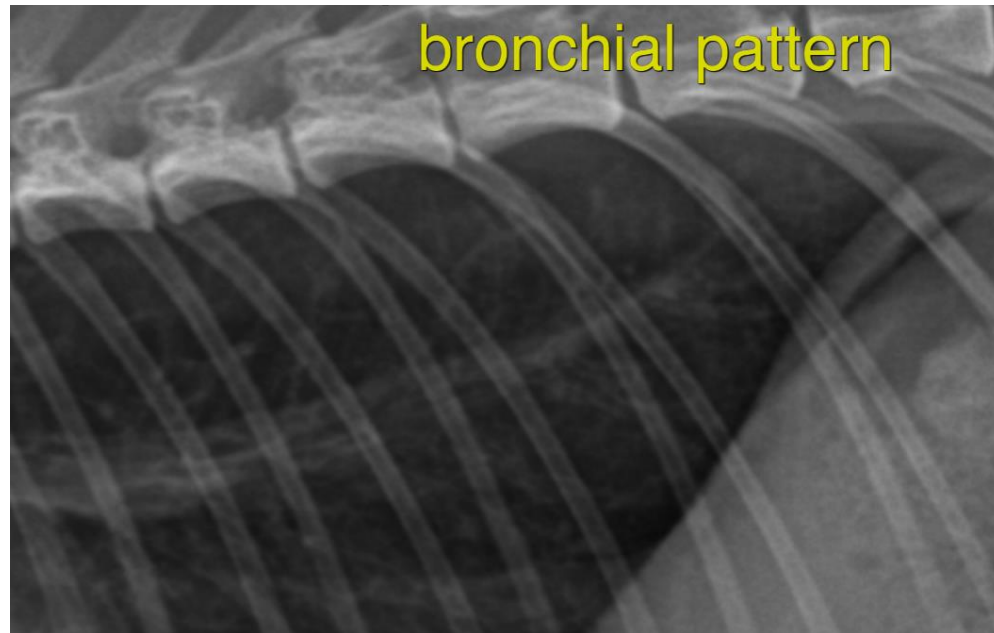
Medhat Meawad

INVOICE

52036

DATE

5-9-22



The information and recommendations provided are based on the images presented by the referring veterinarian/sonographer. No evaluation can be communicated regarding pathology that was not visible in the image/video clips provided.

Thank you for this referral. If the clinical or image interpretation does not parallel your findings or if I can be of any further assistance please contact me.

Nele Eley, DVM, Dr. med. vet., DipECVDI
European Specialist in Veterinary Diagnostic Imaging, Cert. Radiology,
Senior lecturer University of Giessen, Germany, Veterinary Faculty, Department of Radiology
Nele.Eley@sonopath.com