



**PATIENT PRESENTING CLINICAL SIGNS**

Lucy Fish History of L4-L5 hemilaminectomy in October 2018. Recovery at 97% (mild residual left pelvic limb lameness). For the past month, worsening of weakness + ataxia in the left pelvic limb + limping of the right pelvic limb. Normal urination and defecation. No signs of pain.

**SPECIES** Abnormal PE/Chem/CBC/UA Results: Ambulatory with mild right-sided paraparesis and proprioceptive ataxia in the pelvic limbs. No pain elicited

Canine

**MAGNETIC RESONANCE IMAGING STUDY OF THE THORACOLUMBAR SPINE**

**BREED**

T2 and T1-plain and post contrast with and without fat saturation of the thoracolumbar spine available for review.

French Bulldog

**MAGNETIC RESONANCE IMAGING FINDINGS**

**SEX**

The patient has a history of left side hemilaminectomy at L3/4.

FS

The hemilaminectomy site presents within the expected limits. No evidence of a new compressive myelopathy is seen. The dorsal longitudinal ligament is mineralized. There is no evidence of significant changes in the spinal cord or soft tissues in the position of the hemilaminectomy.

**AGE**

8 Years

Focal dorsal subarachnoid space widening with uniformly fluid intense signal and caudal teardrop shape is seen within the mid thoracic spine at T7 and T8. The dilation is most prominent level with T8 where mild to moderate ventral deviation and compression of the spinal cord are seen. Spinal cord edema is noted caudal to the dilated subarachnoid space. There is no evidence of pathologic contrast enhancement.

**INTERPRETED BY**

Nele Eley, DVM  
Dr. med. Vet. DipECVDI

Multiple congenital vertebral malformations within the thoracic spine with hemivertebrae from T5 through T10 and a lumbosacral transitional vertebra are seen.

**HOSPITAL NAME**

Animal Health Partners

**MAGNETIC RESONANCE IMAGING DIAGNOSIS**

- Arachnoid diverticulum with mild to moderate compressive myelopathy T7/8.
- Prior hemilaminectomy L3/4 left sided - no evidence of a new disc hernia; findings within the expected limits.
- Multiple congenital vertebral malformations T5 through T10.
- Lumbosacral transitional vertebra.

**REFERRING VET**

Dr. Greg Kilburn

**INTERPRETATION OF THE FINDINGS & FURTHER RECOMMENDATIONS**

**INVOICE**

52010

The main finding is the presence of focal arachnoid space dilation with fluid intense material and mild to moderate ventral deviation and spinal cord compression at T7 and T8. The findings are compatible with arachnoid diverticulum which may have congenital/developmental or acquired etiopathogenesis. Decompressive surgery could be discussed depending on the severity of the clinical signs.

**DATE**

5-9-22



**PATIENT**

Lucy Fish

**SPECIES**

Canine

**BREED**

French Bulldog

**SEX**

FS

**AGE**

8 Years

**INTERPRETED BY**

Nele Eley, DVM  
Dr. med. Vet. DipECVDI

**HOSPITAL NAME**

Animal Health  
Partners

**REFERRING VET**

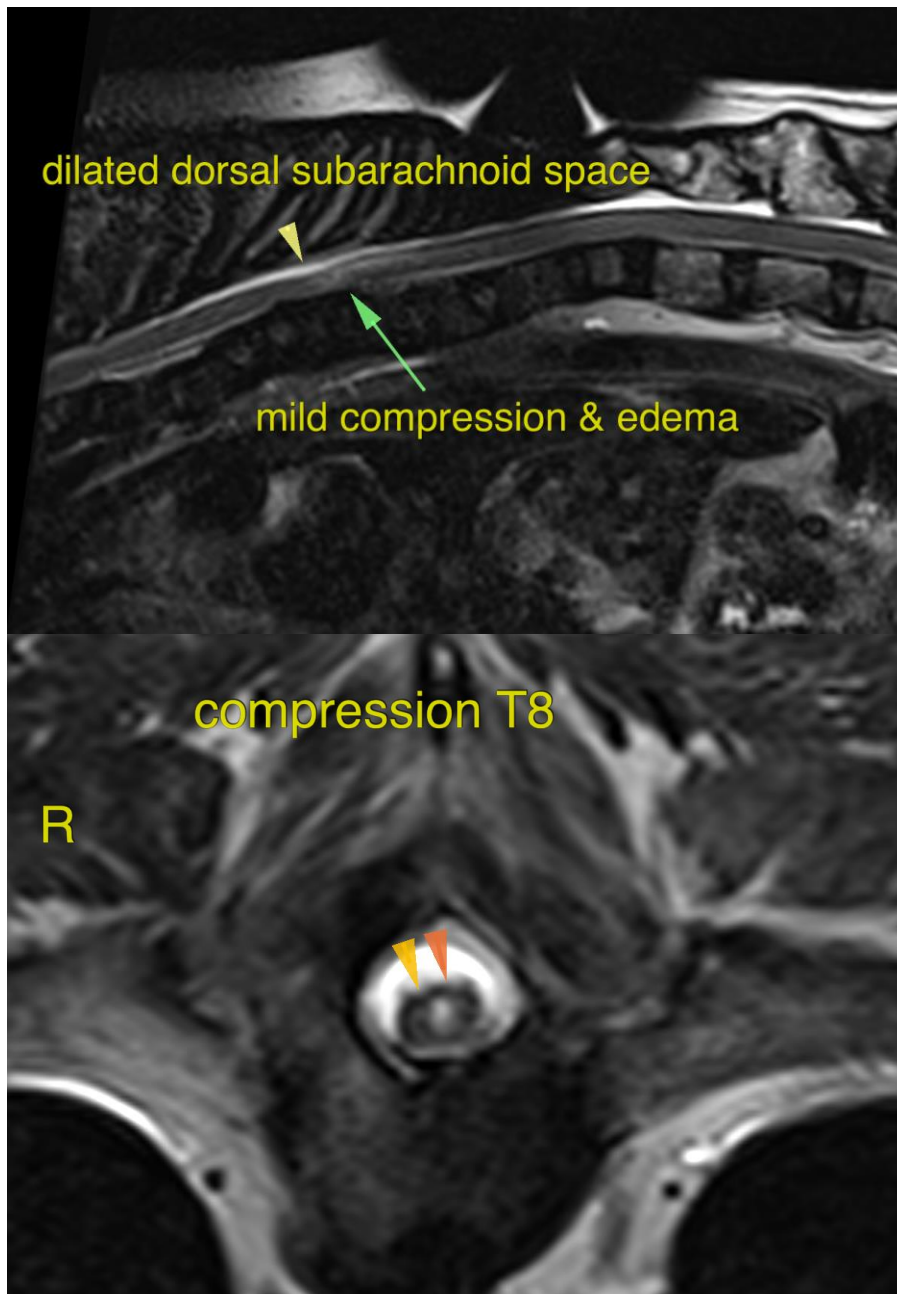
Dr. Greg Kilburn

**INVOICE**

52010

**DATE**

5-9-22





**PATIENT**

Lucy Fish

The information and recommendations provided are based on the images presented by the referring veterinarian/sonographer. No evaluation can be communicated regarding pathology that was not visible in the image/video clips provided.

Thank you for this referral. If the clinical or image interpretation does not parallel your findings or if I can be of any further assistance please contact me.

**SPECIES**

Canine

**Nele Eley**, DVM, Dr. med. vet., DipECVDI  
European Specialist in Veterinary Diagnostic Imaging, Cert. Radiology,  
Senior lecturer University of Giessen, Germany, Veterinary Faculty, Department of Radiology  
Nele.Eley@sonopath.com

**BREED**

French Bulldog

**SEX**

FS

**AGE**

8 Years

**INTERPRETED BY**

Nele Eley, DVM  
Dr. med. Vet. DipECVDI

**HOSPITAL NAME**

Animal Health  
Partners

**REFERRING VET**

Dr. Greg Kilburn

**INVOICE**

52010

**DATE**

5-9-22