



**PATIENT**

Fritz Cummings

**SPECIES**

Canine

**BREED**

Miniature Schnauzer

**SEX**

Male Neutered

**AGE**

8 Years

**INTERPRETED BY**

Nele Eley, DVM  
Dr. med. Vet. DipECVDI

**HOSPITAL NAME**

Truscott Animal  
Hospital

**REFERRING VET**

Medhat Meawad

**INVOICE**

52035

**DATE**

5-9-22

**PRESENTING CLINICAL SIGNS**

owner concerned that Fritz is arching back, fatigued after walking occasionally, b/w shows no abnormalities palpating spine and all MSK of both front and hind legs, there were no concerns R/O any abnormalities in spine of abdomen no heart murmur and O says no coughing, however getting fatigued quickly - we can see minor tracheal change (potential tracheal collapse) - not sure if this can be correlated with the other findings or symptoms

**RADIOGRAPHIC STUDY OF THE THORAX & ABDOMEN**

Right/left lateral and ventrodorsal of the thorax and abdomen totaling 6 images available for review.

**RADIOGRAPHIC FINDINGS**

Number, alignment, and general anatomy of the thoracic and lumbar vertebrae present within normal limits. There is no evidence of aggressive bone lesions or traumatic osseous injury.

**Thorax**

Marked redundancy of the dorsal tracheal ligament is seen on the lateral views of the thorax.

There is a mild generalized bronchial lung pattern which is evenly distributed throughout the lung. No pulmonary masses or nodules are seen.

The vertebral heart score is 10.5.

There is no evidence of mediastinal lymphadenomegaly.

**Abdomen**

The liver margins are slightly beyond the costal arch with rounded lobar margins.

A mild amount of gravel is seen within the stomach.

The radiographic presentation of the kidneys, spleen, and urinary bladder is within the expected limits.

The coxofemoral and stifle joints present within normal limits.

The muscle volume of both hind limbs appears to be adequate and symmetric.

**RADIOGRAPHIC DIAGNOSIS**

- Mild generalized hepatomegaly.
- Redundant dorsal tracheal ligament.
- Normal radiographic presentation of the thoracolumbar spine.



**PATIENT**

Fritz Cummings

**SPECIES**

Canine

**BREED**

Miniature Schnauzer

**SEX**

Male Neutered

**AGE**

8 Years

**INTERPRETED BY**

Nele Eley, DVM  
Dr. med. Vet. DipECVDI

**HOSPITAL NAME**

Truscott Animal  
Hospital

**REFERRING VET**

Medhat Meawad

**INVOICE**

52035

**DATE**

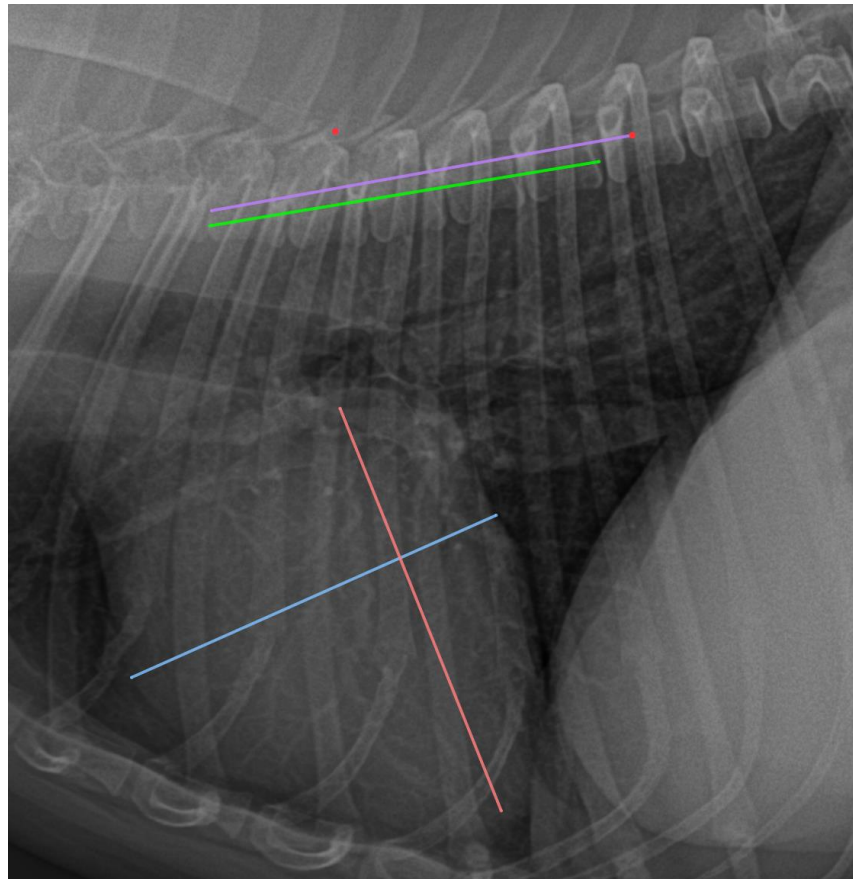
5-9-22

**INTERPRETATION OF THE FINDINGS & FURTHER RECOMMENDATIONS**

Differential diagnosis for the hepatomegaly includes metabolic/endocrine hepatopathy. Diffuse inflammatory/infectious or neoplastic infiltrates are thought unlikely but cannot be ruled out entirely. Correlate with the laboratory values and consider ultrasound as well as parenchymal sampling for further definition if indicated.

The findings of the lung are considered within age related normal limits.

A redundant dorsal tracheal ligament is typically an incidental finding, however, it can be associated with dynamic tracheal disease. Clinical correlation is required.





**PATIENT**

Fritz Cummings

The information and recommendations provided are based on the images presented by the referring veterinarian/sonographer. No evaluation can be communicated regarding pathology that was not visible in the image/video clips provided.

**SPECIES**

Canine

Thank you for this referral. If the clinical or image interpretation does not parallel your findings or if I can be of any further assistance please contact me.

**BREED**

Miniature Schnauzer

**Nele Eley**, DVM, Dr. med. vet., DipECVDI  
European Specialist in Veterinary Diagnostic Imaging, Cert. Radiology,  
Senior lecturer University of Giessen, Germany, Veterinary Faculty, Department of Radiology  
Nele.Eley@sonopath.com

**SEX**

Male Neutered

**AGE**

8 Years

**INTERPRETED BY**

Nele Eley, DVM  
Dr. med. Vet. DipECVDI

**HOSPITAL NAME**

Truscott Animal  
Hospital

**REFERRING VET**

Medhat Meawad

**INVOICE**

52035

**DATE**

5-9-22