

**PATIENT**

Cooper Worthington

SPECIES

Canine

BREED

German Shepherd

SEX

MI

AGE

7 Months

INTERPRETED BYNele Eley, DVM
Dr. med. Vet. DipECVDI**HOSPITAL NAME**Bridgwater
Veterinary Hospital
and Wellness Centre**REFERRING VET**

Dr M. Sra

INVOICE

51999

DATE

5-9-22

PRESENTING CLINICAL SIGNS

May have got head stuck in a tractor yesterday morning - came running from field in pain and not closing his jaw, seems to have discomfort mostly on sides of jaw. Able to eat small amount soft food and chicken broth, able to yawn.

Abnormal PE/Chem/CBC/UA Results: Increased phos 2.44 mmol/L Decreased Amyl 397 U/L, Lipa 129 U/L

COMPUTED TOMOGRAPHIC STUDY OF THE HEAD

Plain and post contrast studies available for review.

COMPUTED TOMOGRAPHIC FINDINGS

The temporomandibular joints are in situ and intact.

There is no evidence of traumatic osseous injury of the facial bones including both maxillae and mandibles.

The dentition is complete and within age related normal limits.

Mild subcutaneous soft tissue swelling is seen level with the occipital area in the upper neck.

The atlas/C1 is incompletely included in the study; however, a fracture of the left wing of the atlas at its base is seen involving the vascular and nerve foramen (alar foramen).

COMPUTED TOMOGRAPHIC DIAGNOSIS

- Traumatic acute complete fracture of the base of the left wing of the atlas/C1 with mild regional hemorrhage.

INTERPRETATION OF THE FINDINGS & FURTHER RECOMMENDATIONS

No evidence of temporomandibular joint or jaw injury is seen however there is traumatic injury of the 1st cervical vertebra (atlas) at the base of its left wing. The injury appears to involve the foramen for the vertebral artery and vein and 1st segmental spinal nerve. Additional injury outside the collimated field of view cannot be ruled out.



PATIENT

Cooper Worthington

SPECIES

Canine

BREED

German Shepherd

SEX

MI

AGE

7 Months

INTERPRETED BY

Nele Eley, DVM
Dr. med. Vet. DipECVDI

HOSPITAL NAME

Bridgwater
Veterinary Hospital
and Wellness Centre

REFERRING VET

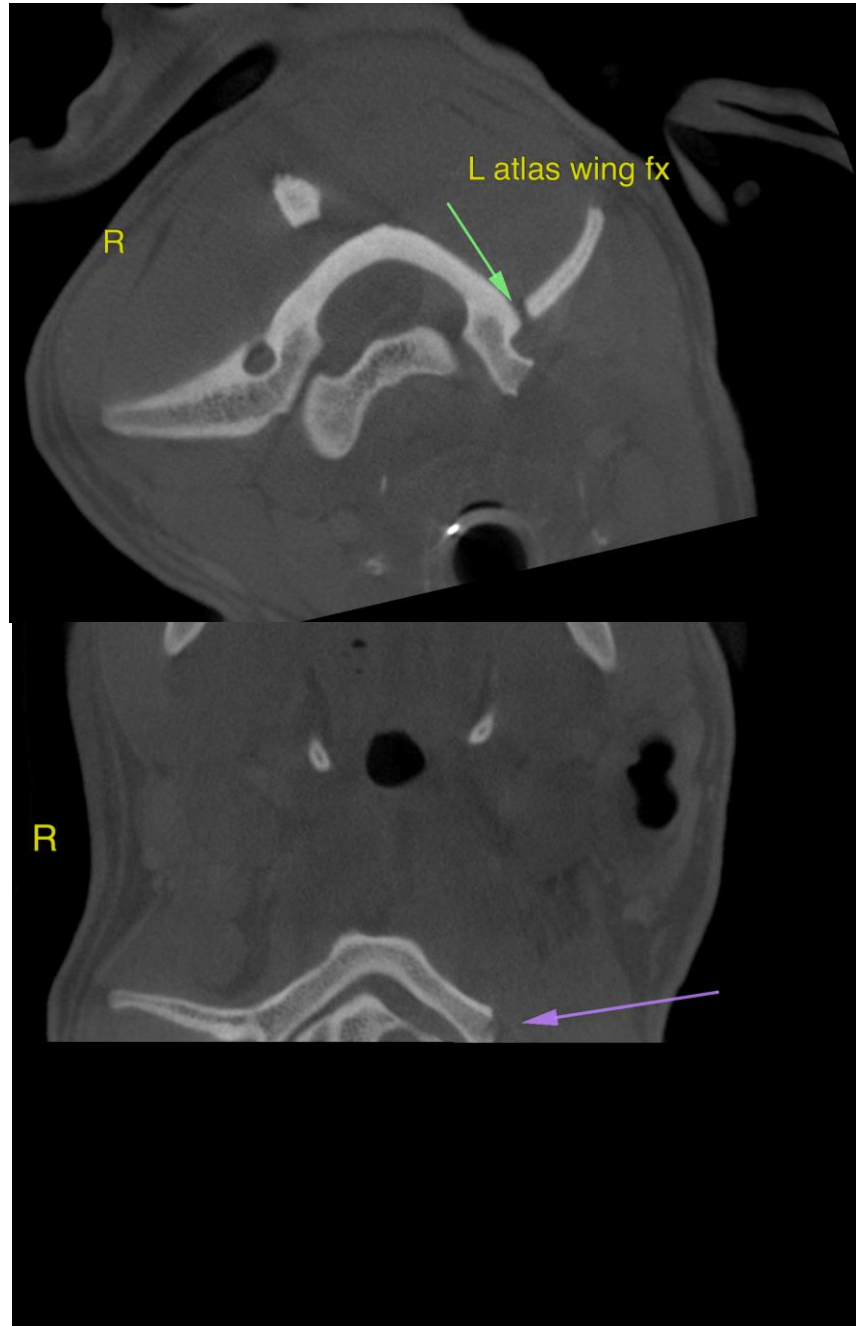
Dr M. Sra

INVOICE

51999

DATE

5-9-22





PATIENT

Cooper Worthington

The information and recommendations provided are based on the images presented by the referring veterinarian/sonographer. No evaluation can be communicated regarding pathology that was not visible in the image/video clips provided.

SPECIES

Canine

Thank you for this referral. If the clinical or image interpretation does not parallel your findings or if I can be of any further assistance please contact me.

BREED

German Shepherd

Nele Eley, DVM, Dr. med. vet., DipECVDI
European Specialist in Veterinary Diagnostic Imaging, Cert. Radiology,
Senior lecturer University of Giessen, Germany, Veterinary Faculty, Department of Radiology
Nele.Eley@sonopath.com

SEX

MI

AGE

7 Months

INTERPRETED BY

Nele Eley, DVM
Dr. med. Vet. DipECVDI

HOSPITAL NAME

Bridgwater
Veterinary Hospital
and Wellness Centre

REFERRING VET

Dr M. Sra

INVOICE

51999

DATE

5-9-22