



PATIENT

Miss Kitty Sutter

PRESENTING CLINICAL SIGNS

Miss Kitty was found and suspected to have been attacked by a dog based on wounds and saliva on the head. Since that time she has had a recurrent swelling on the right side of the face near the eye. The mass has been responsive to antibiotic therapy, aspirates have been consistent with mast cell tumor, or inflammatory changes.

SPECIES

Feline

Abnormal PE/Chem/CBC/UA Results: OBJECTIVE Weight (kg): 99.80 Temp (°F): 100.00 H.R.: 200 R.R.: 40 B.C.S.: 0/9 M.M.: Pink, C.R.T. :1-2 sec Eyes: bright and clear, mild squinting of the right eye. Semi fluctuant region in region of right zygomatic arch. Ears: clean with no inflammation Nose and throat: no abnormality Heart: No noted arrhythmia or pulse deficits, normal subjective peripheral circulation Lungs: normal respiratory sounds, rate and effort Abdomen: soft and non-painful with no noted abnormalities Musculoskeletal: No significant musculoskeletal abnormalities or lameness Integument: Clean and smooth hair coat, thick hair around the space between the right eye and ear with a small scab at the entrance to the right ear. Lymph Nodes: Normal size and firmness Neurological: No mentation, cranial nerve, or neurologic gait abnormalities seen

BREED

DSH

SEX

FS

COMPUTED TOMOGRAPHIC STUDY OF THE HEAD

Plain and post contrast studies available for review.

AGE

3 Years

COMPUTED TOMOGRAPHIC FINDINGS

Extensive thick contrast enhancing soft tissue swelling is seen in the right side of the face starting at the base of the right ear cranial to the parotid salivary gland and extending up to the triadan 104. The total length is 5.5 cm. The swelling is approximately 1.0 cm in thickness. Contrast enhancement is moderate and nonuniform. No evidence of cavitation is seen. There is no evidence of aggressive osteolytic changes of the underlying zygomatic arch or maxilla. The swelling appears to blend into the upper and lower lid of the right eye which are mildly swollen too.

INTERPRETED BY

Nele Eley, DVM
Dr. med. Vet. DipECVDI

HOSPITAL NAME

Mountain West
Veterinary Hospital

The regional lymph nodes including the retropharyngeal and submandibular lymph nodes present within normal limits.

COMPUTED TOMOGRAPHIC DIAGNOSIS

- Flat enhancing soft tissue swelling in the right side of the face from the base of the ear to the rostral maxilla.

REFERRING VET

Burton

INTERPRETATION OF THE FINDINGS & FURTHER RECOMMENDATIONS

The CT findings are compatible with diffuse soft tissue swelling in the right side of the face. The findings are not compatible with an abscess. Severe panniculitis is a potential differential diagnosis as well as excessive scar tissue formation and soft tissue neoplasia such as mast cell tumor and other. Repetition of the sampling could be considered to obtain samples for histology and establish a final diagnosis.

INVOICE

58166

DATE

5-8-23

At this time, there is no evidence of regional lymphadenomegaly.



PATIENT

Miss Kitty Sutter

SPECIES

Feline

BREED

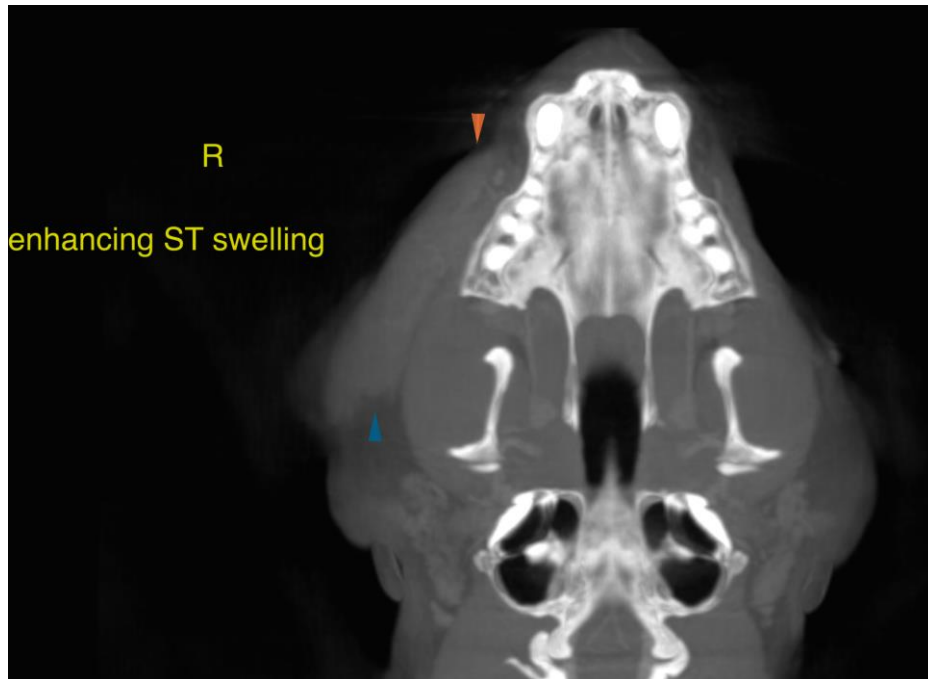
DSH

SEX

FS

AGE

3 Years



INTERPRETED BY

Nele Eley, DVM
Dr. med. Vet. DipECVDI

The information and recommendations provided are based on the images presented by the referring veterinarian/sonographer. No evaluation can be communicated regarding pathology that was not visible in the image/video clips provided.

Thank you for this referral. If the clinical or image interpretation does not parallel your findings or if I can be of any further assistance please contact me.

HOSPITAL NAME

Mountain West
Veterinary Hospital

Nele Eley, DVM, Dr. med. vet., DipECVDI
European Specialist in Veterinary Diagnostic Imaging, Cert. Radiology,
Senior lecturer University of Giessen, Germany, Veterinary Faculty, Department of Radiology
Nele.Eley@sonopath.com

REFERRING VET

Burton

INVOICE

58166

DATE

5-8-23