



PATIENT PRESENTING CLINICAL SIGNS

PATIENT Chewie Rutski chronic upper stridor. Developed otitis externa and unresponsive to typical tresaderm . Follow up visit revealed purulent unilateral (AS) discharge. Cultured as Coagulase neg Staph. Sensitive to gentamicin. Intact tympanic membranes and gentamicin instilled AU. 8d later head tilt to the right.

SPECIES On repeat exam bilateral creamy discharge AU and bilateral tympanic membrane rupture. Sinus rads and tympanic bulla rads performed and sedated ear and naso=-pharyngeal polyp search negative.

Feline Starting P on clavamox (also sensitive on culture) today and gentle steel saline lavage of AU. Abnormal PE/Chem/CBC/UA Results: Normal CBC, chem and BNP.

BREED RADIOGRAPHIC STUDY OF THE HEAD

DSH 2 right oblique and 1 left oblique lateral views totaling 3 images.

RADIOGRAPHIC FINDINGS

SEX Neutered Male The osseous lining of both tympanic bullae appears to be moderately thickened. The pattern of thickening is a moderate generalized thickening with a generalized increase in opacity of the lumen of both tympanic bullae. The frontal sinuses and nasal cavities appear to be aerated. No evidence of aggressive osteolytic changes and no evidence of mass lesions can be identified.

AGE RADIOGRAPHIC DIAGNOSIS

23 Weeks

- Suspect bilateral tympanic bullae hyperostosis with opacification of the bullae lumen

INTERPRETATION OF FINDINGS & FURTHER RECOMMENDATIONS

INTERPRETED BY Nele Eley (Ondreka), DVM Dr. med. vet., DipECVDI

The radiographic changes suggest potential for chronic bilateral otitis media with bulla osteitis and exudative effusion versus empyema. Cholesteatoma, soft tissue mass and a bulla hemorrhage cannot be ruled out as differential diagnoses. However, these appear far less likely based on the patient demographics and clinical history. Consider further otoscopic workup. Should the results of the otoscopic workup remain unclear and/or should the patient remain unresponsive to the initiated treatment, CT would be an option for further definition.

HOSPITAL NAME Belvedere Vet Center

REFERRING VET Dr. Lawrence Eden

INVOICE

37518

DATE

5/8/22



PATIENT

Chewie Rutski

SPECIES

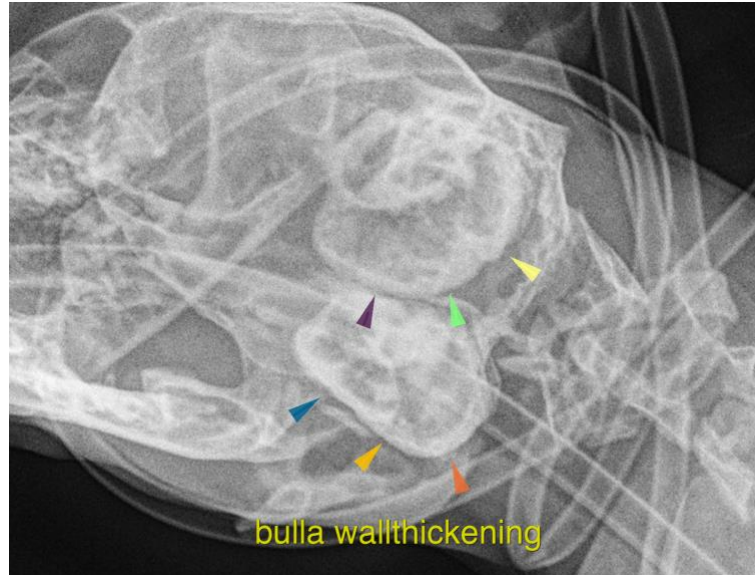
Feline

BREED

DSH

SEX

Neutered Male



AGE

23 Weeks

The information and recommendations provided are based on the images presented by the referring veterinarian. No evaluation can be communicated regarding pathology that was not visible in the image/video clips provided.

Thank you for this referral. If the clinical or image interpretation does not parallel your findings or if I can be of any further assistance please contact me.

INTERPRETED BY

Nele Eley (Ondreka),
DVM Dr. med. vet.,
DipECVDI

Nele Eley (Ondreka), DVM, Dr. med. vet., DipECVDI
European Specialist in Veterinary Diagnostic Imaging, Cert. Radiology,
Senior lecturer University of Giessen/Germany, Veterinary Faculty, Department of Radiology.
Nele.Eley@sonopath.com

HOSPITAL NAME

Belvedere Vet Center

REFERRING VET

Dr. Lawrence Eden

INVOICE

37518

DATE

5/8/22