



PATIENT

Bitsy Boyle

PRESENTING CLINICAL SIGNS

presented for COHAT, bilateral swelling rostrally suspected tooth root abscessation

SPECIES

Canine

COMPUTED TOMOGRAPHIC STUDY OF THE DENTAL ARCADES

Plain study available for review.

BREED

Chihuahua

COMPUTED TOMOGRAPHIC FINDINGS

Severe periodontal space widening, loss of the lamina dura, and small dental nasal fistula are seen associated with the two mesial roots of the triadan 108.

SEX

FS

The mesial and distal roots of the triadan 109 reveal severe periodontal space widening and loss of the lamina dura of the dental alveolus as well.

Severe periodontal space widening of the tooth elements 202 and 203 is seen with regional soft tissue swelling. No overt aggressive osteolytic changes are seen.

AGE

11 Years

Severe periodontal space widening, loss of the lamina dura, and small dental nasal fistula associated with the mesial roots of the triadan 208 are present.

The roots of the triadan 209 present moderate periodontal space widening.

INTERPRETED BY

Nele Eley, DVM
Dr. med. Vet. DipECVDI

Severe periodontal space widening with loss of the lamina dura is seen with the distal root of the triadan 408.

COMPUTED TOMOGRAPHIC DIAGNOSIS

- Severe multifocal periodontal disease with tooth root abscessations of the triadans 108, 109, 202, 203, 208, 209, and 408.
- Small dental nasal fistulae with currently no significant evidence of rhinitis associated with the dental root abscesses of the triadans 108 and 208.

HOSPITAL NAME

South Bay Animal
Hospital & Pet Resort

INTERPRETATION OF THE FINDINGS & FURTHER RECOMMENDATIONS

Consider dental abscesses of the triadans 108, 109, 202, 203, 208, 209, and 408.

REFERRING VET

Dr. Ravinder Atwal

The soft tissue swelling level with the left rostral maxilla may well represent cellulitis, abscess, or a drainage tract. Granuloma, hematoma, and neoplasia are thought unlikely but cannot be ruled out entirely. Clinical correlation is required.

INVOICE

51991

DATE

5-8-22



PATIENT

Bitsy Boyle

SPECIES

Canine

BREED

Chihuahua

SEX

FS

AGE

11 Years

INTERPRETED BY

Nele Eley, DVM
Dr. med. Vet. DipECVDI

HOSPITAL NAME

South Bay Animal
Hospital & Pet Resort

REFERRING VET

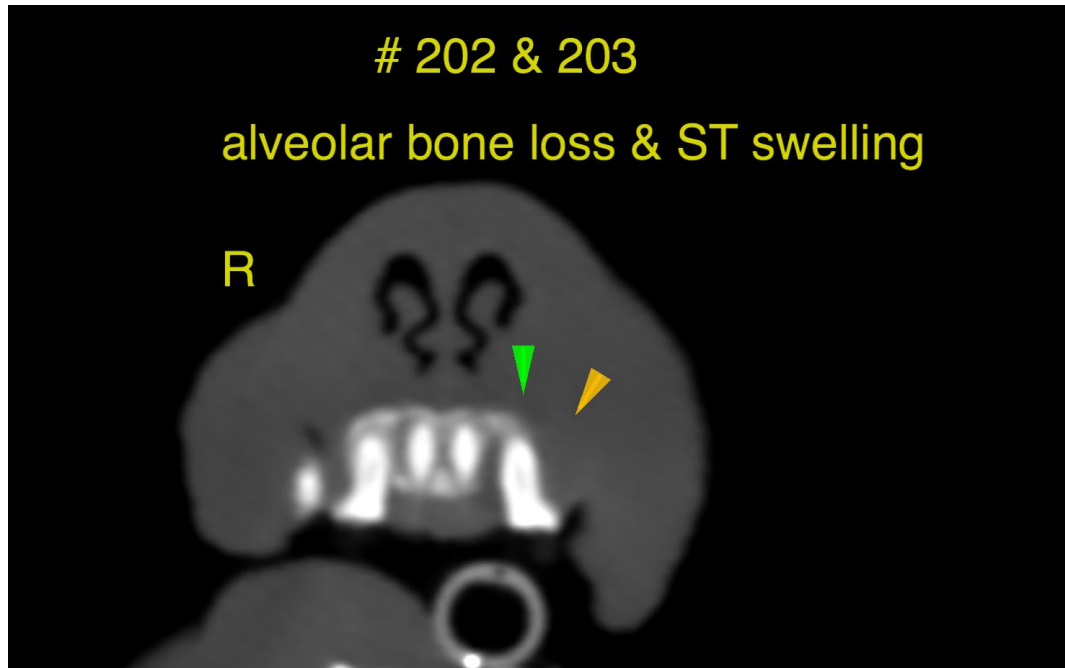
Dr. Ravinder Atwal

INVOICE

51991

DATE

5-8-22



The information and recommendations provided are based on the images presented by the referring veterinarian/sonographer. No evaluation can be communicated regarding pathology that was not visible in the image/video clips provided.

Thank you for this referral. If the clinical or image interpretation does not parallel your findings or if I can be of any further assistance please contact me.

Nele Eley, DVM, Dr. med. vet., DipECVDI
European Specialist in Veterinary Diagnostic Imaging, Cert. Radiology,
Senior lecturer University of Giessen, Germany, Veterinary Faculty, Department of Radiology
Nele.Eley@sonopath.com