



PATIENT PRESENTING CLINICAL SIGNS

Obi Tompkins 2 months ago anxiety started O's took to the vet and vet mentioned to do CBD. They didn't. Ataxia started over weekend. His hind limbs are crossing over each other sometimes. Has been having trouble going upstairs and jumping onto his spot on couch
SPECIES Abnormal PE/Chem/CBC/UA Results: spinal pain, decreased CP, normal to increased segmental reflexes

Canine

COMPUTED TOMOGRAPHIC STUDY OF THE CAUDAL THORACIC & LUMBAR SPINE

BREED

Myelogram with lumbar puncture available for review. The thoracic spine is imaged from T9 onwards caudally.

Beagle

COMPUTED TOMOGRAPHIC FINDINGS

SEX

Excessive epidural leakage noted.

MN

Mild lumbosacral spondylosis deformans is seen.

AGE

There appears to be a series of mild intervertebral disc protrusions between T12/13, T13/L1, L1/2, and L2/3. L2/3 presents moderate spondylosis deformans.

8 Years

A mild protrusion of isoattenuating disc material is seen into the ventral epidural space between T9 and T10, too.

INTERPRETED BY

Nele Eley, DVM
 Dr. med. Vet. DipECVDI

The impression of deviation of the contrast media in the ventral epidural space can be artificially enhanced by the epidural leakage of contrast media.

COMPUTED TOMOGRAPHIC DIAGNOSIS

HOSPITAL NAME

Animal Surgical Center

- Mild serial chronic intervertebral disc protrusions between T12/13, T13/L1, L1/2, L2/3.
- Mild intervertebral disc protrusion T9/10.
- Degenerative lumbosacral stenosis.

INTERPRETATION OF THE FINDINGS & FURTHER RECOMMENDATIONS

REFERRING VET

Yorktown Animal Hospital

The CT study supports the presence of mild chronic intervertebral disc protrusions in the caudal thoracic and cranial lumbar spine between T12-L3.

Moderate spondylosis deformans is noted between L2 and L3.

Mild spondylosis deformans is noted between L7 and S1.

INVOICE

Mild intervertebral disc protrusion is seen between T9 and T10.

58164

DATE

5-7-23



PATIENT

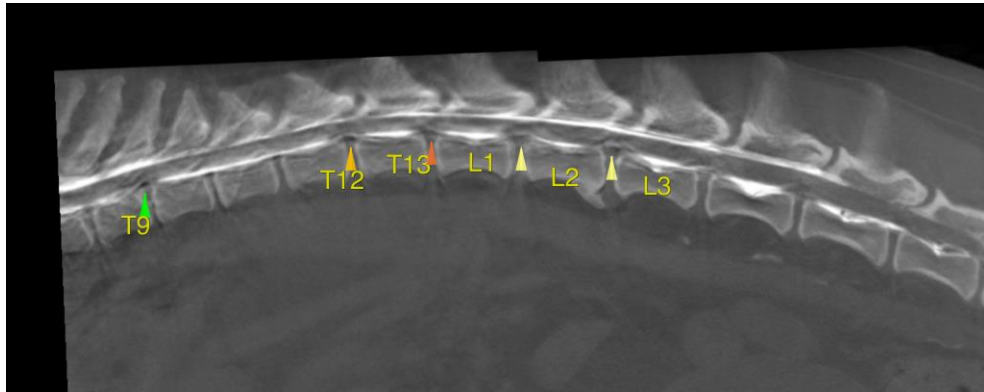
Obi Tompkins

SPECIES

Canine

BREED

Beagle



SEX

MN

AGE

8 Years

INTERPRETED BY

Nele Eley, DVM
Dr. med. Vet. DipECVDI

HOSPITAL NAME

Animal Surgical
Center

REFERRING VET

Yorktown Animal
Hospital

INVOICE

58164

DATE

5-7-23

The information and recommendations provided are based on the images presented by the referring veterinarian/sonographer. No evaluation can be communicated regarding pathology that was not visible in the image/video clips provided.

Thank you for this referral. If the clinical or image interpretation does not parallel your findings or if I can be of any further assistance please contact me.

Nele Eley, DVM, Dr. med. vet., DipECVDI
European Specialist in Veterinary Diagnostic Imaging, Cert. Radiology,
Senior lecturer University of Giessen, Germany, Veterinary Faculty, Department of Radiology
Nele.Eley@sonopath.com