



PATIENT

Poseidon Alvarez

PRESENTING CLINICAL SIGNS

Acute onset limping Left hind leg

SPECIES

Canine

RADIOGRAPHIC STUDY OF THE STIFLES

Mediolateral views of both stifles totaling 3 images available for review.

BREED

Pitbull Mix

Mild articular swelling of both stifle joint is noted.

SEX

MN

There is a mild amount of periarticular osteophytes accentuated in both the left and right femoral trochlea and distal pole of the patella. No obvious displacement of the popliteal sesamoid bones is seen.

There is no enlargement of the popliteal lymph nodes appreciated.

AGE

11

No evidence of aggressive bone lesions is identified.

RADIOGRAPHIC DIAGNOSIS

- Bilateral stifle arthropathy with mild signs of nonerosive osteoarthritis.

INTERPRETED BY

Nele Eley, DVM
Dr. med. Vet. DipECVDI

INTERPRETATION OF THE FINDINGS & FURTHER RECOMMENDATIONS

Mild bilateral nonerosive osteoarthritis of the stifle joints is seen. Differential diagnosis includes degenerative joint disease with or without cranial cruciate ligament or meniscal injury and inflammatory arthropathy. Trauma overload injury and other all are thought less likely. Correlation with the clinical palpation is required in order to determine the potential presence of cranial cruciate ligament failure. If that is not the case, further diagnostic testing may comprise aspiration and analysis of synovia, sedated palpation, stifle ultrasound, or MRI.

HOSPITAL NAME

Rockaway Animal
Hospital

REFERRING VET

Dr. Maniar

INVOICE

51981

DATE

5-7-22



PATIENT

Poseidon Alvarez

SPECIES

Canine

BREED

Pitbull Mix

SEX

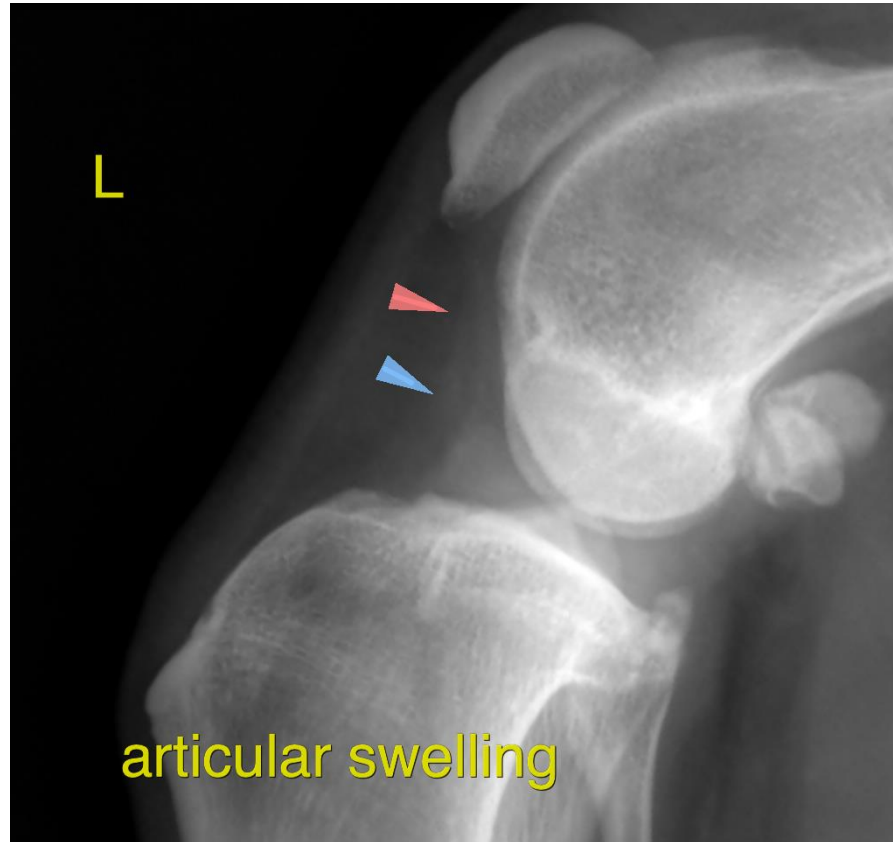
MN

AGE

11

INTERPRETED BY

Nele Eley, DVM
Dr. med. Vet. DipECVDI



HOSPITAL NAME

Rockaway Animal
Hospital

REFERRING VET

Dr. Maniar

INVOICE

51981

DATE

5-7-22

The information and recommendations provided are based on the images presented by the referring veterinarian/sonographer. No evaluation can be communicated regarding pathology that was not visible in the image/video clips provided.

Thank you for this referral. If the clinical or image interpretation does not parallel your findings or if I can be of any further assistance please contact me.

Nele Eley, DVM, Dr. med. vet., DipECVDI
European Specialist in Veterinary Diagnostic Imaging, Cert. Radiology,
Senior lecturer University of Giessen, Germany, Veterinary Faculty, Department of Radiology
Nele.Eley@sonopath.com