



PATIENT

Dax Mehan

PRESENTING CLINICAL SIGNS

Dax is a 5m/o intact male Labrador Retriever presented for limping and non-weight bearing on the right hind leg. On his exam he had inflammation and crepitus on the 3th right digit of his hind leg. He was also reactive towards any palpation around that area. We are suspected that he might have fracture or subluxation of the P3 or P2.

SPECIES

Canine

RADIOGRAPHIC STUDY OF THE HIND PAWS

Mediolateral, dorsoplantar, and oblique views of the right and left hind paws totaling 9 images available for review.

BREED

Labrador Retriever

RADIOGRAPHIC FINDINGS

Extensive soft tissue swelling is noted around the 4th digit of the right hind paw. Narrowing of the proximal interphalangeal joint space is seen in this digit. A faintly radiolucent line is separating a wedge shaped fragment from the proximopalmar and lateral aspect of the middle phalanx in the 4th digit. A mild step formation is seen. The line of separation appears to extend into the joint space. There is only minimal displacement. The presumed fracture margins are rounded with a mild amount of smooth new bone formation.

SEX

Male

AGE

5 Months

RADIOGRAPHIC DIAGNOSIS

- Suspect subacute traumatic complete slab fracture of the proximal, lateral, and palmar aspect of the middle phalanx of the 4th digit in the right hind limb with articular involvement of the proximal interphalangeal joint.

INTERPRETED BY

Nele Eley, DVM
Dr. med. Vet. DipECVCI

INTERPRETATION OF THE FINDINGS & FURTHER RECOMMENDATIONS

The radiographic findings suggest traumatic osseous injury of the middle phalanx involving the proximal interphalangeal joint in the 4th digit in the right hind paw. Based on the radiographic appearance, subacute injury appears more likely than a very acute event. Presence of concurrent infection / cellulitis should be ruled out. Based on the radiographic presentation, hematoma or edema are the most likely causes of the concurrent soft tissue swelling.

HOSPITAL NAME

Beaches-Fallingbrook
Veterinary Clinic

REFERRING VET

Dr Matt Haghghat

INVOICE

51986

DATE

5-7-22



PATIENT

Dax Mehan

SPECIES

Canine

BREED

Labrador Retriever

SEX

Male

AGE

5 Months

INTERPRETED BY

Nele Eley, DVM
Dr. med. Vet. DipECVDI

HOSPITAL NAME

Beaches-Fallingbrook
Veterinary Clinic

REFERRING VET

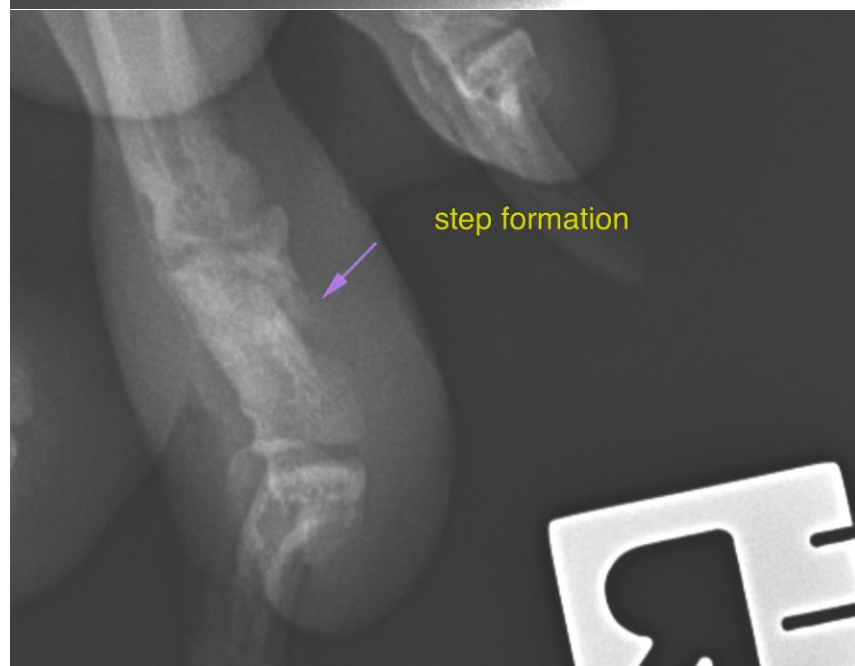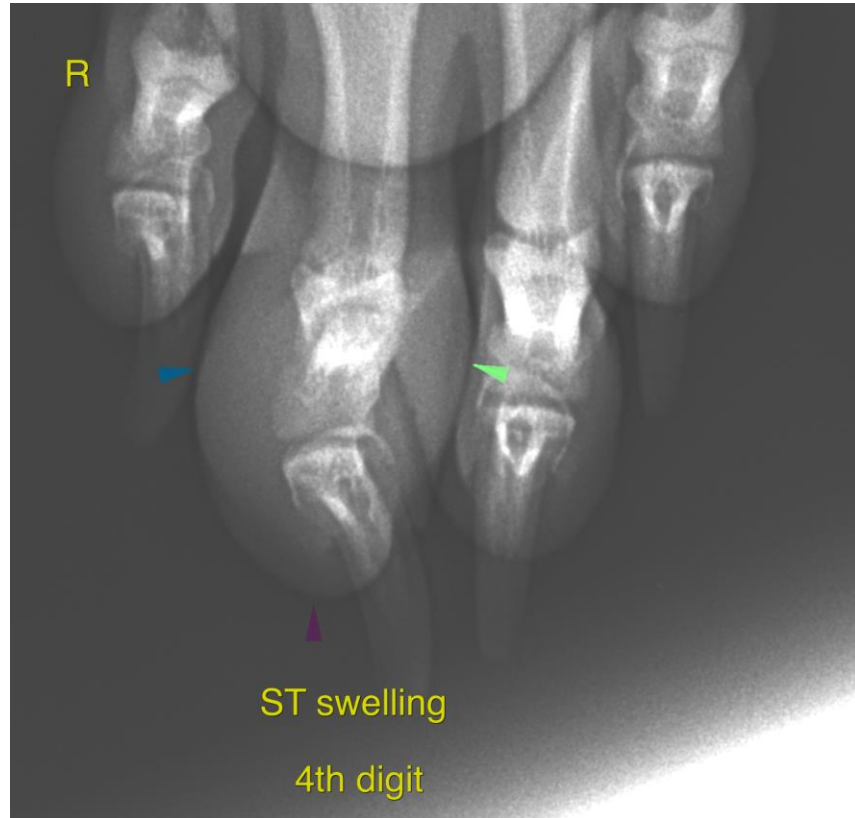
Dr Matt Haghightat

INVOICE

51986

DATE

5-7-22





PATIENT

Dax Mehan

The information and recommendations provided are based on the images presented by the referring veterinarian/sonographer. No evaluation can be communicated regarding pathology that was not visible in the image/video clips provided.

SPECIES

Canine

Thank you for this referral. If the clinical or image interpretation does not parallel your findings or if I can be of any further assistance please contact me.

BREED

Labrador Retriever

Nele Eley, DVM, Dr. med. vet., DipECVDI
European Specialist in Veterinary Diagnostic Imaging, Cert. Radiology,
Senior lecturer University of Giessen, Germany, Veterinary Faculty, Department of Radiology
Nele.Eley@sonopath.com

SEX

Male

AGE

5 Months

INTERPRETED BY

Nele Eley, DVM
Dr. med. Vet. DipECVDI

HOSPITAL NAME

Beaches-Fallingbrook
Veterinary Clinic

REFERRING VET

Dr Matt Haghighat

INVOICE

51986

DATE

5-7-22