



PATIENT

Bella Breeze Woods

SPECIES

Canine

BREED

Mini Poodle

SEX

FE

AGE

7 Months

INTERPRETED BY

Nele Eley, DVM
Dr. med. Vet. DipECVDI

HOSPITAL NAME

Boca Park Animal
Hospital

REFERRING VET

Dr. Corinna Gorgon

INVOICE

51982

DATE

5-7-22

PRESENTING CLINICAL SIGNS

Patient presented for spay, upon intake owner states has been vomiting. Owner found vomit yesterday with a fruit pit inside (either nectarine vs peach). Spay not performed, gave SQ fluids and cerenia injection. NPO overnight and repeated rads this morning. Pet BAR and no vomiting occurring

RADIOGRAPHIC STUDY OF THE ABDOMEN

1 set of 3 radiographs dated 5-6 and 1 recheck radiograph of the abdomen dated 5-7 totaling 4 images available for review.

RADIOGRAPHIC FINDINGS

The abdominal serosal detail is maintained throughout both studies.

There is no evidence of abnormal small intestinal dilation; however, a square, faintly mineral opaque structure of 1 x 0.5 cm is seen in the recheck radiograph in the cranial abdomen with one nondilated small intestinal loop being turgid in appearance.

RADIOGRAPHIC DIAGNOSIS

- Small intestinal foreign material versus summation artifact.

INTERPRETATION OF THE FINDINGS & FURTHER RECOMMENDATIONS

The radiographic studies reveal no evidence of two populations of small bowel yet on the recheck radiographs there is the impression of presence of a small square foreign object within the small intestine. I cannot entirely rule out this representing summation artifact, yet I would recommend narrow clinical monitoring and recheck radiographs or abdominal ultrasound at any time the patient resumes vomiting.



PATIENT

Bella Breeze Woods

SPECIES

Canine

BREED

Mini Poodle

SEX

FE

AGE

7 Months

INTERPRETED BY

Nele Eley, DVM
Dr. med. Vet. DipECVDI

HOSPITAL NAME

Boca Park Animal
Hospital

REFERRING VET

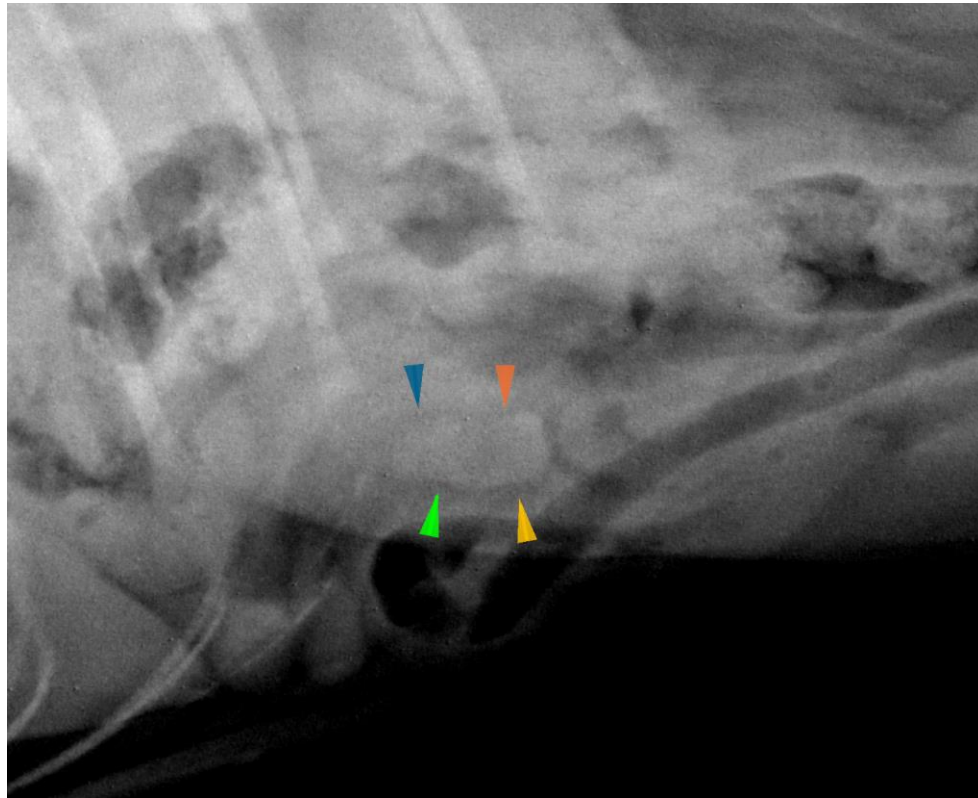
Dr. Corinna Gorgon

INVOICE

51982

DATE

5-7-22



The information and recommendations provided are based on the images presented by the referring veterinarian/sonographer. No evaluation can be communicated regarding pathology that was not visible in the image/video clips provided.

Thank you for this referral. If the clinical or image interpretation does not parallel your findings or if I can be of any further assistance please contact me.

Nele Eley, DVM, Dr. med. vet., DipECVDI
European Specialist in Veterinary Diagnostic Imaging, Cert. Radiology,
Senior lecturer University of Giessen, Germany, Veterinary Faculty, Department of Radiology
Nele.Eley@sonopath.com