



PATIENT

Luna Murphy

PRESENTING CLINICAL SIGNS

Limping occasionally on left hind leg. On physical exam under sedation, no drawer movement but x-ray shows effusion. Can not rule out partial cruciate.

SPECIES

Canine

RADIOGRAPHIC STUDY OF THE STIFLES

Mediolateral and craniocaudal views of both stifles totaling 4 images available for review.

BREED

Bully

RADIOGRAPHIC FINDINGS

The right stifle joint presents within normal limits. No evidence of articular swelling, patella tendon injury, or tibial thrust is seen. The subchondral bones are intact and smooth. There is no evidence of degenerative joint disease.

SEX

Female Spayed

The left hind limb presents mild loss in muscle volume.

Moderate articular swelling of the left stifle joint is noted with cranial thrust of the tibia. A moderate amount of periarticular osteophytes is seen in the patella, femoral trochlea, fabellae, and tibial plateau, as well as the popliteal sesamoid bone.

AGE

5 Years

RADIOGRAPHIC DIAGNOSIS

- Moderate osteoarthritis of the left stifle joint with radiographic evidence of cranial cruciate ligament injury.
- Disuse atrophy of the left hind limb musculature.

INTERPRETED BY

Nele Eley, DVM
Dr. med. Vet. DipECVDI

INTERPRETATION OF THE FINDINGS & FURTHER RECOMMENDATIONS

The radiographic findings are compatible with biomechanical function loss of the left cranial cruciate ligament. Moderate osteoarthritis of the left stifle joint is seen. The findings strongly suggest cranial cruciate ligament injury such as partial or complete rupture. Presence of medial meniscal injury cannot be ruled out. Note the presence of moderate osteoarthritic changes of the left stifle joint and atrophy of the left hind limb musculature indicating presence of chronic disuse. Surgical intervention should be considered in order to address the presumed biomechanical instability of the left cranial cruciate ligament and prevent further damage to the joint.

HOSPITAL NAME

Truscott Animal
Hospital

REFERRING VET

Dr. Medhat Meawad

INVOICE

58151

DATE

5-6-23



PATIENT

Luna Murphy

SPECIES

Canine

BREED

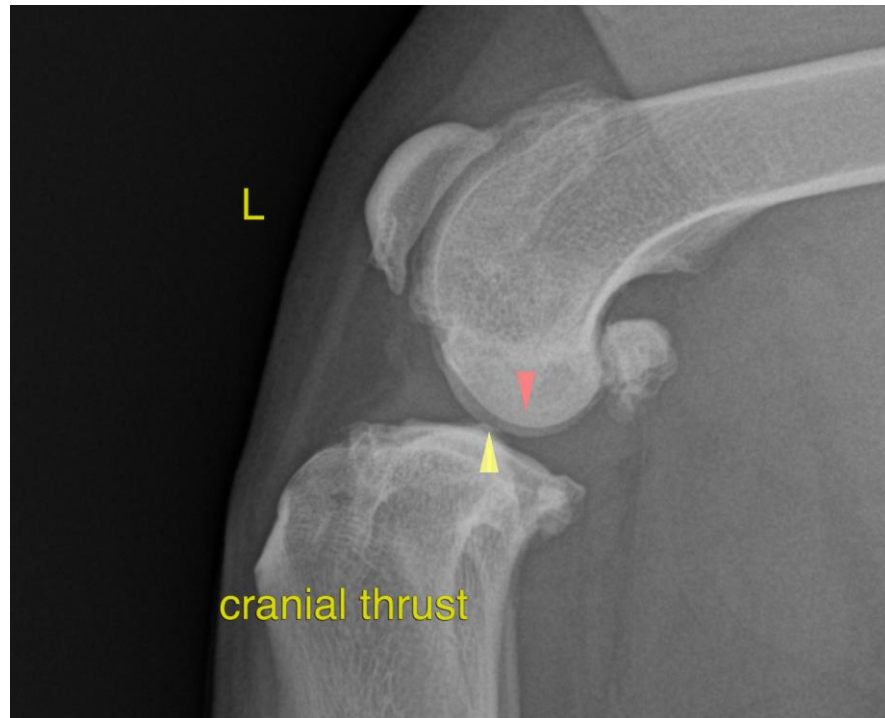
Bully

SEX

Female Spayed

AGE

5 Years



INTERPRETED BY

Nele Eley, DVM
Dr. med. Vet. DipECVDI

The information and recommendations provided are based on the images presented by the referring veterinarian/sonographer. No evaluation can be communicated regarding pathology that was not visible in the image/video clips provided.

HOSPITAL NAME

Truscott Animal
Hospital

Thank you for this referral. If the clinical or image interpretation does not parallel your findings or if I can be of any further assistance please contact me.

Nele Eley, DVM, Dr. med. vet., DipECVDI
European Specialist in Veterinary Diagnostic Imaging, Cert. Radiology,
Senior lecturer University of Giessen, Germany, Veterinary Faculty, Department of Radiology
Nele.Eley@sonopath.com

REFERRING VET

Dr. Medhat Meawad

INVOICE

58151

DATE

5-6-23