

**PATIENT**

Saedy Gardiner

PRESENTING CLINICAL SIGNS

VD pelvic rads show the RHL femoral neck is mottled with a pathological fracture. Very suspicious of OSA. Cannot readily assess L7 or sacrum on VD as feces are overlapping. Lateral view is suspicious of cranial sacral lucency and caudal L7 may have a linear lucency.

SPECIES

Canine

RADIOGRAPHIC FINDINGS**Pelvis****BREED**

Border Collie

Severe extensive moth eaten osteolysis is seen in the right femoral head and neck. The femoral head is collapsed. There is a curvilinear radiolucent line at the transition between the femoral head and femoral neck. The transition zones to the unaffected bone in the proximal metaphysis and epiphysis are long and indistinct.

SEX

Female Spayed

The right femoral musculature is severely reduced in volume.

There is no evidence of additional aggressive osteolytic lesions in the lumbosacral area.

AGE

12

The radiolucent presentation of the caudal 7th vertebra and cranial sacrum is a result of mild long axis rotation and superimposition with the lumbosacral neuroforamen, sacroiliac joint, and fecal matter within the colon.

RADIOGRAPHIC DIAGNOSIS**INTERPRETED BY**Nele Eley, DVM
Dr. med. Vet. DipECVDI

- Monostotic aggressive osteolytic lesion of the right proximal femur with pathologic fracture.
- Severe disuse atrophy of the right hind limb musculature.

INTERPRETATION OF THE FINDINGS & FURTHER RECOMMENDATIONS**HOSPITAL NAME**River Valley
Veterinary Wellness
Clinic

The radiographic study reveals a monostotic aggressive osteolytic lesion and pathologic fracture in the right proximal femur. Primary neoplasia of bone such as osteosarcoma is considered by far most likely. Metastases of another primary tumor and less likely hematogenous fungal infection with osteomyelitis cannot be ruled out entirely as differential diagnoses. There is a pathologic fracture of the right femoral neck and severe disuse atrophy of the right hind limb musculature indicating chronically reduced weight bearing.

REFERRING VET

Dr. Stelfox

INVOICE

51976

DATE

5-6-22



PATIENT

Saedy Gardiner

SPECIES

Canine

BREED

Border Collie

SEX

Female Spayed

AGE

12

INTERPRETED BY

Nele Eley, DVM
Dr. med. Vet. DipECVDI

HOSPITAL NAME

River Valley
Veterinary Wellness
Clinic

REFERRING VET

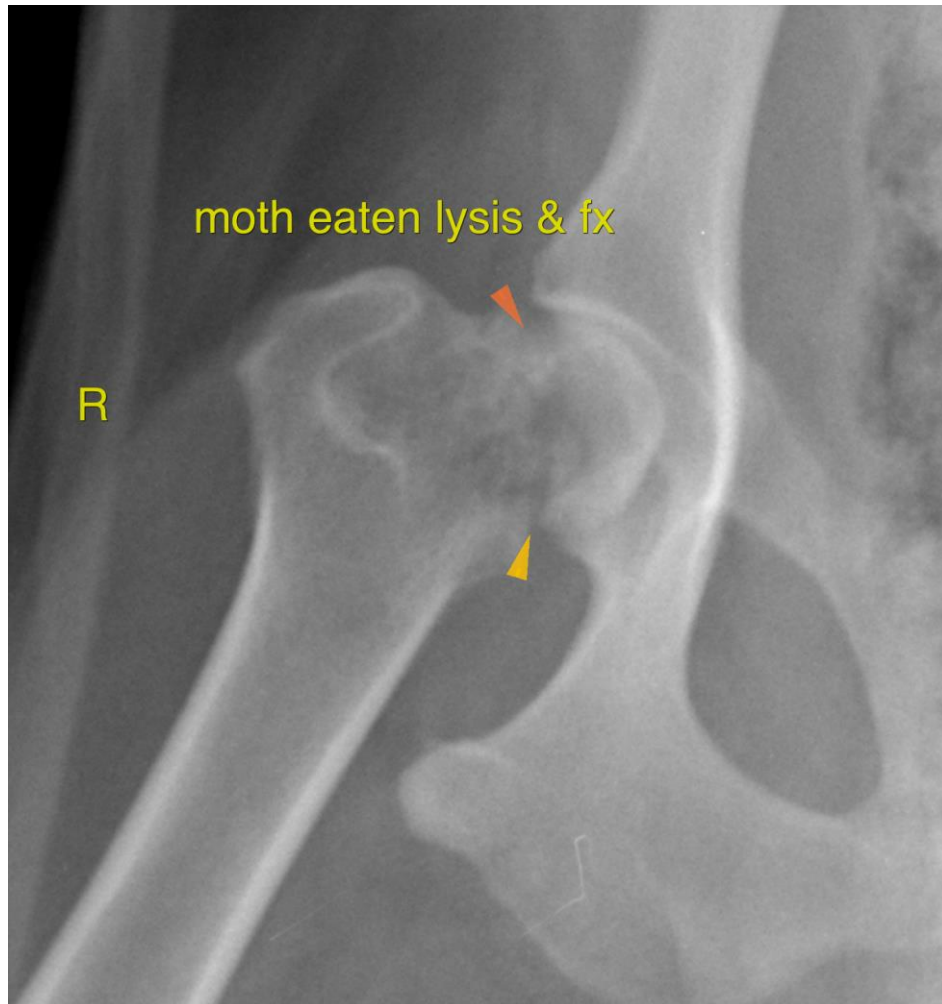
Dr. Stelfox

INVOICE

51976

DATE

5-6-22



The information and recommendations provided are based on the images presented by the referring veterinarian/sonographer. No evaluation can be communicated regarding pathology that was not visible in the image/video clips provided.

Thank you for this referral. If the clinical or image interpretation does not parallel your findings or if I can be of any further assistance please contact me.

Nele Eley, DVM, Dr. med. vet., DipECVDI
European Specialist in Veterinary Diagnostic Imaging, Cert. Radiology,
Senior lecturer University of Giessen, Germany, Veterinary Faculty, Department of Radiology
Nele.Eley@sonopath.com