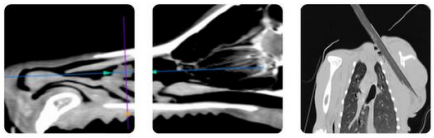

Teleradiology
Educational Teleconsultation Services™

PATIENT
Pinky Dotson

SPECIES
Canine

BREED
Boxer

SEX
Male

AGE
10Y

WEIGHT
73

INTERPRETED BY
Nele Eley (Ondreka), DVM Dr. med. vet., DipECVDI

IMAGING PERFORMED BY
Tiffany- CVT/ Dr. George

HOSPITAL NAME
Green Prairie Animal Hospital

REFERRING VET
Dr. George Eales

INVOICE
74883

DATE
5-5-26

PRESENTING CLINICAL SIGNS

mass felt on palpation during routine dental within jaw- concerned about osteosarcoma.

COMPUTED TOMOGRAPHIC STUDY OF THE HEAD

Plain and post contrast studies are available for review.

COMPUTED TOMOGRAPHIC FINDINGS

The right rostral mandible presents a well-defined ossifying mass measuring approximately 17 x 12 x 14mm laterally adjacent to the triadan 404. The lesion is associated with early cortical bone lysis along the lateral aspect of the right rostral mandible and mild periosteal reaction as well as regionally increased contrast enhancement.

Gingivostomal soft tissue swelling with focal area of bone lysis is present between the teeth 303 and 304.

Multiple moderate dental root resorption is seen accentuating the incisor and canine teeth in all quadrants.

The regional submandibular and retropharyngeal lymph nodes present within normal limits.

COMPUTED TOMOGRAPHIC DIAGNOSIS

- Ossifying locally aggressive right mandibular mass with early cortical bone lysis.
- Focal lysis with associated gingivostomal soft tissue swelling – left rostral mandible 303-304 region.

INTERPRETATION OF FINDINGS & FURTHER RECOMMENDATIONS

The CT study suggests locally aggressive behavior of the right rostral mandibular mass. Primary neoplasia of bone such as osteosarcoma or multilobulated osteosarcoma is considered a primary differential diagnosis. Osteoma, ossifying fibroma, dystrophic calcification, and calcinosis circumscripta are considered less likely but cannot be excluded completely. Biopsy of the right mandibular lesion is recommended for definitive diagnosis.

The focal lytic lesion within the left rostral mandible may represent ameloblastoma/acanthomatous epulis, dentigerous cyst, locally invasive fibroma, or other odontogenic neoplasia. This lesion presents less aggressive features; however, biopsy and histopathology will be required for definitive diagnosis as well.

SonoPath
FOSTERING THE ART OF VETERINARY MEDICINE™

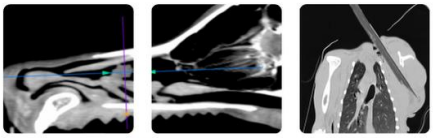

Teleradiology
Educational Teleconsultation Services™

SonoPath.com info@sonopath.com 1.800.838.4268

PATIENT

Pinky Dotson

SPECIES

Canine

BREED

Boxer

SEX

Male

AGE

10Y

WEIGHT

73

INTERPRETED BY

Nele Eley (Ondreka), DVM Dr. med. vet., DipECVDI

IMAGING PERFORMED BY

Tiffany- CVT/ Dr. George

HOSPITAL NAME

Green Prairie Animal Hospital

REFERRING VET

Dr. George Eales

INVOICE

74883

DATE

5-5-26

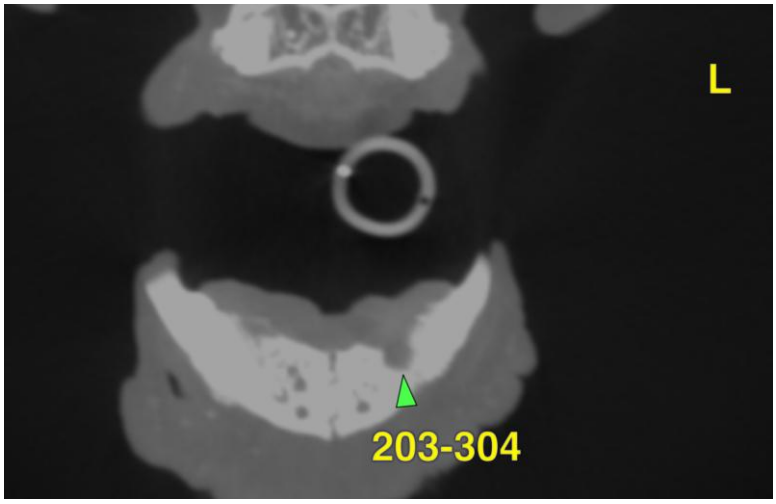

SonoPath
FOSTERING THE ART OF VETERINARY MEDICINE™

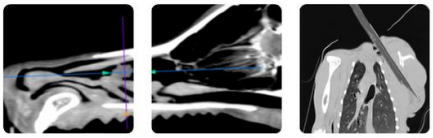

Teleradiology
Educational Teleconsultation Services™

SonoPath.com info@sonopath.com 1.800.838.4268

PATIENT

Pinky Dotson

SPECIES

Canine

BREED

Boxer

SEX

Male

AGE

10Y

WEIGHT

73

INTERPRETED BY

Nele Eley (Ondreka), DVM Dr. med. vet., DipECVDI

IMAGING PERFORMED BY

Tiffany- CVT/ Dr. George

HOSPITAL NAME

Green Prairie Animal Hospital

REFERRING VET

Dr. George Eales

INVOICE

74883

DATE

5-5-26

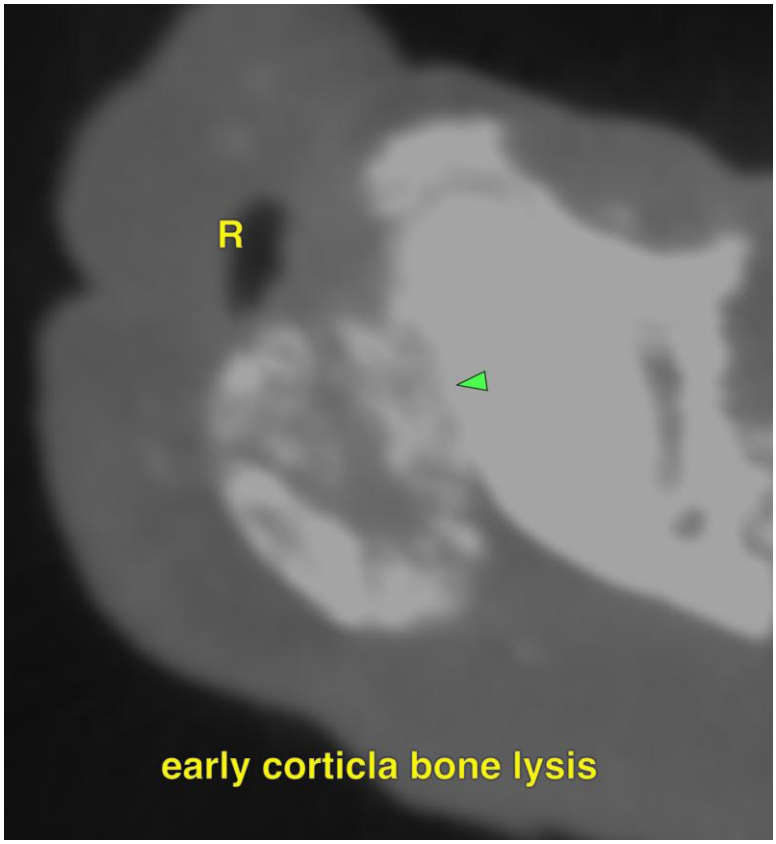

The information and recommendations provided are based on the images presented by the referring veterinarian. No evaluation can be communicated regarding pathology that was not visible in the image/video clips provided.

Thank you for this referral. If the clinical or image interpretation does not parallel your findings or if I can be of any further assistance please contact me.

Nele Eley (Ondreka), DVM, Dr. med. vet., DipECVDI
European Specialist in Veterinary Diagnostic Imaging, Cert. Radiology,
Senior lecturer University of Giessen/Germany, Veterinary Faculty, Department of Radiology.
info@sonopath.com