



**PATIENT**

Beau Joynt

**PRESENTING CLINICAL SIGNS**

Leg had been a bit sore- started in the fall- o thought might be hips, but was limping on the left. Would warm out of the limp. 2 weeks ago was running at the dog park with some other dogs, came back and was holding leg up. Has improved a little bit since then.

**SPECIES**

Canine

Abnormal PE/Chem/CBC/UA Results: Positive Cr drawer sign in flexion less in extension. Small medial buttress, Positive CTT, No crepitus, no clicking. TDX: Partial tera left CCL

**ULTRASONOGRAPHIC FINDINGS**

**BREED**

Std Poodle

**Left Stifle**

A moderate amount of anechoic effusion is present in the supra- and infra- patellar recesses of the left stifle joint. There appears to be marked swelling of the synovium and capsular thickening. The infrapatellar fat pad presents moderate heterogeneity. A mild amount of periarticular osteophytes is seen.

**SEX**

MN

A thick stump of discontinuous and heterogeneous fibers of the cranial cruciate ligament is seen at the intercondylar eminence of the tibia. There may be a thinner continuous part of the ligament maintained. The caudal cruciate ligament is well seen and continuous.

**AGE**

8 Years, 11 Months

No evidence of meniscal changes is noted.

**ULTRASONOGRAPHIC DIAGNOSIS**

- Moderate left stifle osteoarthritis with cranial cruciate ligament injury.

**INTERPRETED BY**

Nele Eley, DVM  
Dr. med. Vet. DipECVDI

**INTERPRETATION OF THE FINDINGS & FURTHER RECOMMENDATIONS**

The ultrasonographic study reveals extensive tearing of the cranial cruciate ligament. A thinner band of cranial cruciate ligament fibers may be maintained, yet the impression based on the ultrasonographic examination is that most fibers are disrupted. At this time, no evidence of meniscal injury was found on ultrasound. Consider surgical intervention in order to address the presumed biomechanical instability and prevent further damage to the articular structures.

**HOSPITAL NAME**

Westview Veterinary  
Hospital

**REFERRING VET**

Dr. Brian Barnes

**INVOICE**

51916

**DATE**

5-4-22



**PATIENT**

Beau Joynt

**SPECIES**

Canine

**BREED**

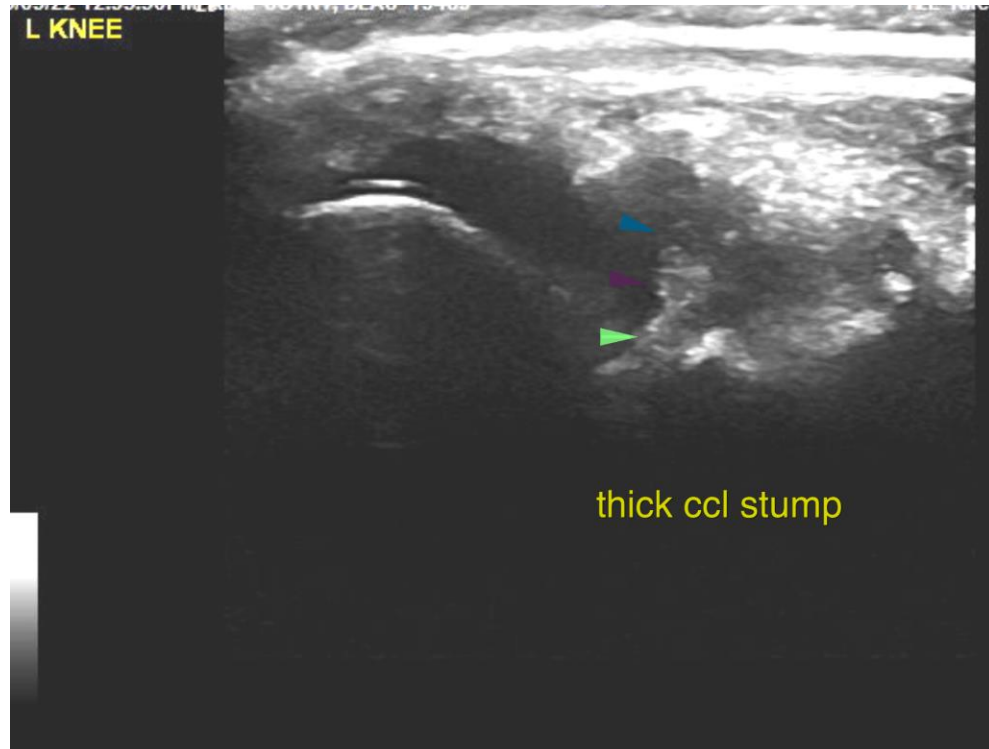
Std Poodle

**SEX**

MN

**AGE**

8 Years, 11 Months



**INTERPRETED BY**

Nele Eley, DVM  
Dr. med. Vet. DipECVDI

The information and recommendations provided are based on the images presented by the referring veterinarian/sonographer. No evaluation can be communicated regarding pathology that was not visible in the image/video clips provided.

**HOSPITAL NAME**

Westview Veterinary  
Hospital

Thank you for this referral. If the clinical or image interpretation does not parallel your findings or if I can be of any further assistance please contact me.

**Nele Eley**, DVM, Dr. med. vet., DipECVDI  
European Specialist in Veterinary Diagnostic Imaging, Cert. Radiology,  
Senior lecturer University of Giessen, Germany, Veterinary Faculty, Department of Radiology  
Nele.Eley@sonopath.com

**REFERRING VET**

Dr. Brian Barnes

**INVOICE**

51916

**DATE**

5-4-22