



PATIENT

Little Guy Porter

PRESENTING CLINICAL SIGNS

Dog went deaf according to owner in one day. Was diagnosed with fungal infection at rDVM and treated with enrofloxacin dex solution, cultures and fungal serology were negative
Abnormal PE/Chem/CBC/UA Results: none

SPECIES

Canine

COMPUTED TOMOGRAPHIC STUDY OF THE HEAD

Plain and post contrast studies available for review.

BREED

Pug

COMPUTED TOMOGRAPHIC FINDINGS

The patient is a brachycephalic dog with shortened facial bones and dome shaped calvarium, reduced frontal sinuses, and reduced number and folding of the nasal conchae and turbinates. Mild mucosal swelling is noted in the ventral aspect of the left nasal cavity.

SEX

MN

The dentition is incomplete. Multifocal moderate periodontal disease is noted accentuating the triadans 107, 108, 109, 207, 208, 209, 307, 308, 309, 310, 407, 408, 409, and 410.

The regional lymph nodes present within normal limits.

AGE

11 Years

The left tympanic bulla is filled with fluid attenuating contrast negative material. No significant changes of the osseous lining of the tympanic bulla are seen. The conformation of both tympanic bullae and auditory meatuses is narrow. Mild thickening of the epithelial lining of both external auditory meatuses with mildly increased contrast enhancement is seen. The right tympanic bulla presents within normal limits. No evidence of meningeal thickening is noted and there is no evidence of inner ear involvement.

INTERPRETED BY

Nele Eley, DVM
Dr. med. Vet. DipECVDI

COMPUTED TOMOGRAPHIC DIAGNOSIS

- Left sided otitis media.
- Bilateral otitis externa.
- Nondestructive rhinitis - left sided.
- Multifocal periodontal disease.

HOSPITAL NAME

Boca Park Animal Hospital

INTERPRETATION OF THE FINDINGS & FURTHER RECOMMENDATIONS

REFERRING VET

Ensign

The CT study reveals presence of left sided otitis media and bilateral otitis externa. Further otoscopic/video-otoscopic workup is recommended with sampling. Bulla osteotomy might be considered in case of repeated lacking treatment response to the medial management. At this time, there is no evidence of intracranial extension.

INVOICE

52222

Consider dental workup.

DATE

5-31-22



PATIENT

Little Guy Porter

SPECIES

Canine

BREED

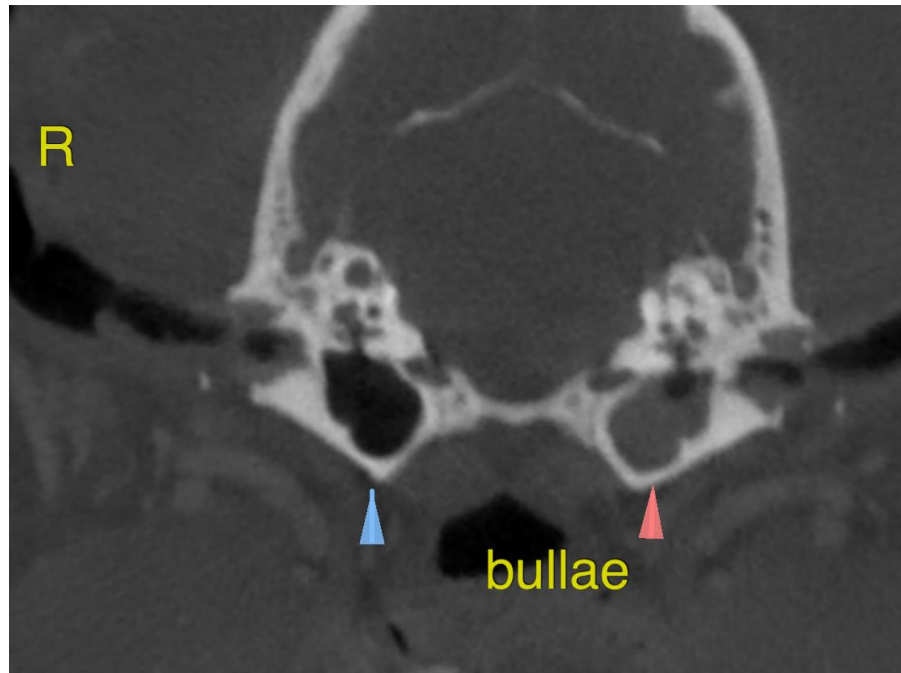
Pug

SEX

MN

AGE

11 Years



INTERPRETED BY

Nele Eley, DVM
Dr. med. Vet. DipECVDI

The information and recommendations provided are based on the images presented by the referring veterinarian/sonographer. No evaluation can be communicated regarding pathology that was not visible in the image/video clips provided.

HOSPITAL NAME

Boca Park Animal
Hospital

Thank you for this referral. If the clinical or image interpretation does not parallel your findings or if I can be of any further assistance please contact me.

Nele Eley, DVM, Dr. med. vet., DipECVDI
European Specialist in Veterinary Diagnostic Imaging, Cert. Radiology,
Senior lecturer University of Giessen, Germany, Veterinary Faculty, Department of Radiology
Nele.Eley@sonopath.com

REFERRING VET

Ensign

INVOICE

52222

DATE

5-31-22