



**PATIENT**

Brax Mandrozos

**PRESENTING CLINICAL SIGNS**

prevented severe coughing no crackles and mild wheeze. As per O, coughing developed last Friday. Rule out tracheal collapse vs. kennel cough vs pneumonia. Temperature is within normal limit and other vital within normal limit.

**SPECIES**

Canine

**RADIOGRAPHIC STUDY OF THE THORAX**

Right/left lateral and ventrodorsal views of the thorax totaling 5 images available for review.

**BREED**

Shih Tzu

**RADIOGRAPHIC FINDINGS**

Moderate to severe flattening of the cervical trachea is seen and accentuates the level of the thoracic inlet. The radiographic study does not reveal concurrent bronchial collapse of intrathoracic tracheal collapse.

**SEX**

Male

The degree of pulmonary inflation is fair on all available images. A moderate generalized bronchointerstitial lung pattern is noted. Occasional peribronchial cuffing is seen and is accentuated more in the expiratory views.

**AGE**

7 Years

No evidence of abnormal mediastinal widening is noted.

There is no evidence of cardiomegaly or specific chamber enlargement of the heart. The vertebral heart score is 9.8 which is within the reference range.

**INTERPRETED BY**

Nele Eley, DVM  
Dr. med. Vet. DipECVDI

The thoracic boundaries present within normal limits.

Gastric aerophagia is noted.

**HOSPITAL NAME**

Truscott Animal  
Hospital

**RADIOGRAPHIC DIAGNOSIS**

- Dynamic tracheal disease.
- Bronchointerstitial lung pattern.

**REFERRING VET**

Dr. Medhat Meawad

**INTERPRETATION OF THE FINDINGS & FURTHER RECOMMENDATIONS**

The radiographic study reveals evidence of dynamic tracheal disease. The collapsing tracheas are accentuated in the caudal cervical area. The degree of collapse appears to be moderate to severe.

The bronchointerstitial lung pattern may well be enhanced by the fair to moderate degree of pulmonary inflation and within age related normal limits. However, concurrent lower airway disease such as allergic bronchopneumopathy or infectious bronchitis cannot be ruled out entirely.

**INVOICE**

52188

**DATE**

5-31-22



**PATIENT**

Brax Mandrozoz

**SPECIES**

Canine

**BREED**

Shih Tzu

**SEX**

Male

**AGE**

7 Years

**INTERPRETED BY**

Nele Eley, DVM  
Dr. med. Vet. DipECVDI

**HOSPITAL NAME**

Truscott Animal  
Hospital

**REFERRING VET**

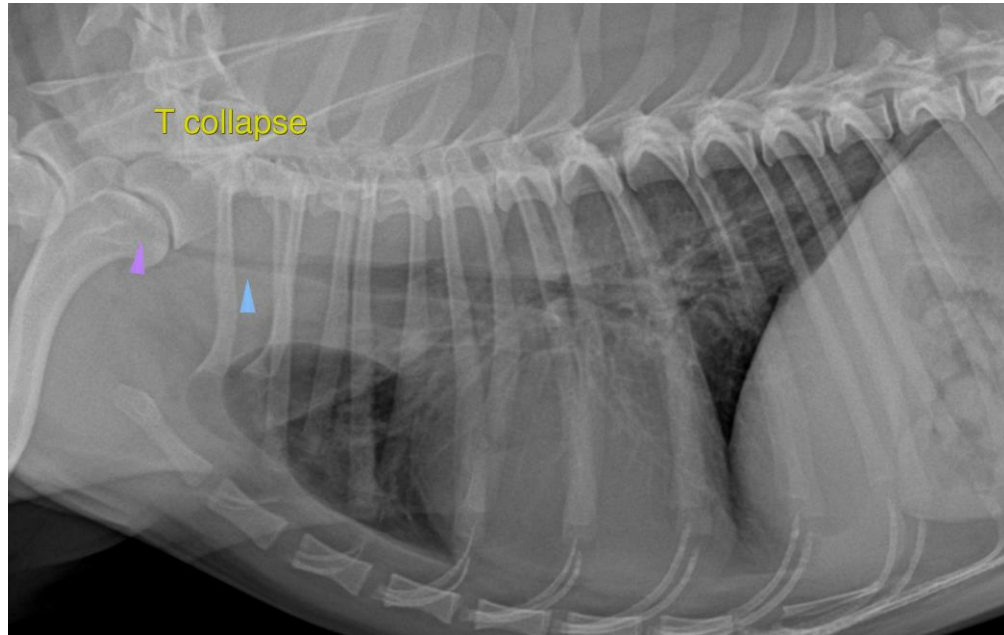
Dr. Medhat Meawad

**INVOICE**

52188

**DATE**

5-31-22



The information and recommendations provided are based on the images presented by the referring veterinarian/sonographer. No evaluation can be communicated regarding pathology that was not visible in the image/video clips provided.

Thank you for this referral. If the clinical or image interpretation does not parallel your findings or if I can be of any further assistance please contact me.

**Nele Eley**, DVM, Dr. med. vet., DipECVDI  
European Specialist in Veterinary Diagnostic Imaging, Cert. Radiology,  
Senior lecturer University of Giessen, Germany, Veterinary Faculty, Department of Radiology  
Nele.Eley@sonopath.com