



PATIENT

Liberty Belle Rosen

PRESENTING CLINICAL SIGNS

mild coughing episodes, no shortness of breath, no exercise intolerance
Abnormal PE/Chem/CBC/UA Results: Blood test results within normal limits

SPECIES

Canine

RADIOGRAPHIC STUDY OF THE THORAX

Right/left lateral and ventrodorsal views of the thorax totaling 3 images available for review.

BREED

Mixed

RADIOGRAPHIC FINDINGS

Multiple mild to severe spondyloses are seen within the thoracic spine and considered unrelated to the reason of presentation.

SEX

FS

Osseous remodeling of the costochondral junctions and periarticular margins of the elbow and shoulder joints is present as well.

The cervical trachea diameter is slightly reduced in the left lateral view cranial to the thoracic inlet. The intrathoracic trachea appears to be wide. No evidence of bronchial collapse is seen.

AGE

13 Years

The lung presents a moderate generalized bronchointerstitial pattern with occasional peripheral cylindrical bronchiectasis.

Mild esophageal aerophagia is noted.

INTERPRETED BY

Nele Eley, DVM
Dr. med. Vet. DipECVDI

The cardiac silhouette presents within normal limits. There is no evidence of generalized cardiomegaly or specific chamber enlargement. The vertebral heart score is 10.2 which is within the reference range.

No evidence of abnormal mediastinal widening is noted.

HOSPITAL NAME

Balmy Beach Pet
Hospital

RADIOGRAPHIC DIAGNOSIS

- Moderate chronic bronchial lung pattern.
- Dynamic tracheal disease.

REFERRING VET

Dr. Singh

INTERPRETATION OF THE FINDINGS & FURTHER RECOMMENDATIONS

The radiographic findings suggest potential for chronic lower airway disease such as irritant bronchitis, allergic bronchopneumopathy, or infectious bronchitis including viral, bacterial, and less likely parasitic. There also appears to be the potential for dynamic tracheal disease even though the radiographic narrowing of the tracheal lumen is limited to the cervical trachea and mild. Consider further definition by airway endoscopy with airway sampling depending on the severity and duration of the clinical signs.

INVOICE

52176

DATE

5-30-22



PATIENT

Liberty Belle Rosen

SPECIES

Canine

BREED

Mixed

SEX

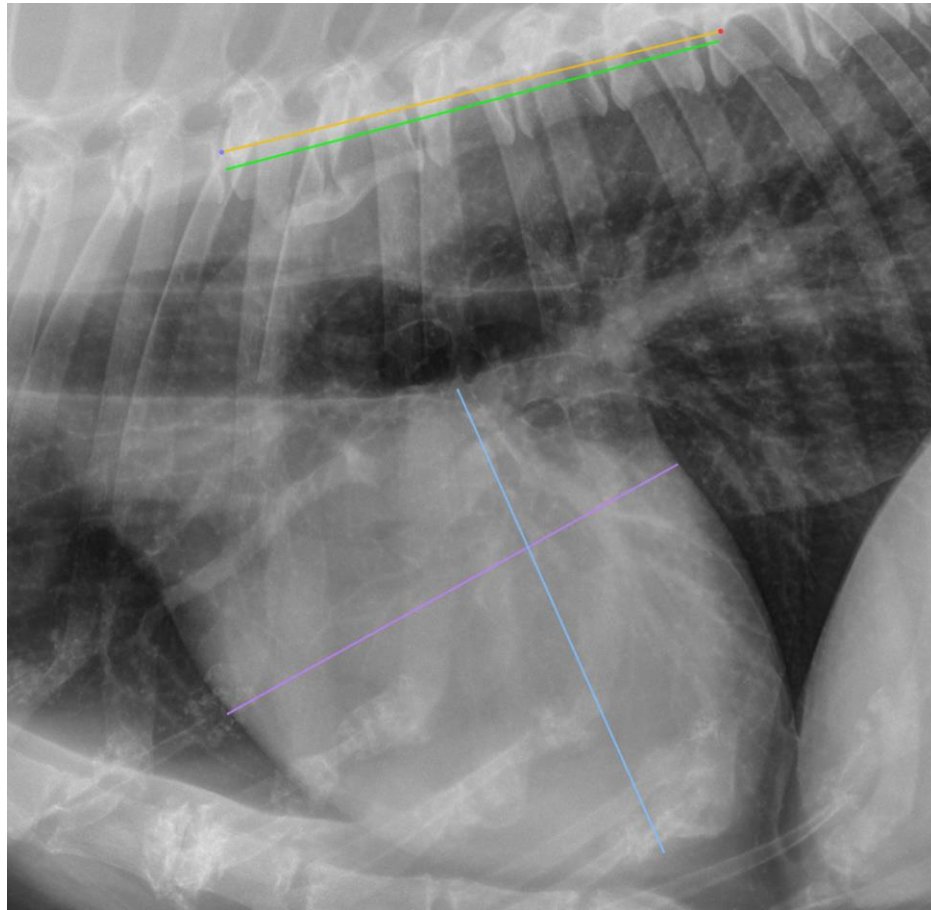
FS

AGE

13 Years

INTERPRETED BY

Nele Eley, DVM
Dr. med. Vet. DipECVDI



HOSPITAL NAME

Balmy Beach Pet
Hospital

REFERRING VET

Dr. Singh

INVOICE

52176

DATE

5-30-22

The information and recommendations provided are based on the images presented by the referring veterinarian/sonographer. No evaluation can be communicated regarding pathology that was not visible in the image/video clips provided.

Thank you for this referral. If the clinical or image interpretation does not parallel your findings or if I can be of any further assistance please contact me.

Nele Eley, DVM, Dr. med. vet., DipECVDI
European Specialist in Veterinary Diagnostic Imaging, Cert. Radiology,
Senior lecturer University of Giessen, Germany, Veterinary Faculty, Department of Radiology
Nele.Eley@sonopath.com