



**PATIENT PRESENTING CLINICAL SIGNS**

**Lucky Min** Here for suddenly limping since Saturday P is having a hard time putting weight on her left hind leg. Getting worst pet has been running a little more than usual.

**SPECIES RADIOGRAPHIC STUDY OF THE LEFT STIFLE & PELVIS**

**Canine** Mediolateral views of the left stifle and lateral views of the pelvis totaling 7 images available for review.

**BREED RADIOGRAPHIC FINDINGS**

**Labrador Retriever** Moderate articular swelling of the left stifle joint is seen. There is a moderate amount of periarticular osteophyte accentuating the femoral trochlea, distal pole of the patella, and cranial margin of the tibial plateau. No obvious cranial thrust of the tibia is seen. The stifle joint is extended on the mediolateral views. There is no evidence of aggressive bone lesions.

**SEX**

**Spayed Female** Mild muscle atrophy of the left hind limb is present.  
The patient appears to be obese.

**AGE**

**6 Years** Both coxofemoral joints present no evidence of dysplasia or osteoarthritis.  
The pelvic bones present within normal limits.

**INTERPRETED BY**

**Nele Eley (Ondreka), DVM Dr. med. vet., DipECVDI** The right stifle is included on the craniocaudal view and presents evidence of mild degenerative joint disease.  
The lumbosacral junction presents within normal limits.

**RADIOGRAPHIC DIAGNOSIS**

**HOSPITAL NAME**

**Animal Paradise Hospital**

- Moderate articular swelling and osteoarthritis of the left stifle joint
- Disuse atrophy of the left hind limb musculature
- Radiographically normal coxofemoral joints and lumbosacral junction

**INTERPRETATION OF FINDINGS & FURTHER RECOMMENDATIONS**

**REFERRING VET**

**Dr. Kristen Hellwarth**

The radiographic study reveals moderate left stifle osteoarthritis. Cranial cruciate ligament pathology and meniscopathy are the most likely underlying causes. However, primary degenerative joint disease, overload injury, trauma, or inflammatory arthropathy cannot be ruled out entirely as differential diagnoses. Correlate with clinical palpation.

**INVOICE**

37331

**DATE**

5/3/22



**PATIENT**

Lucky Min

**SPECIES**

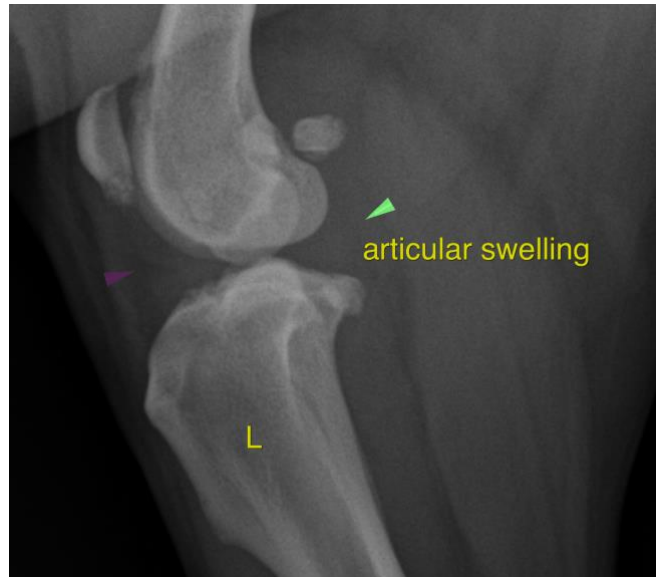
Canine

**BREED**

Labrador Retriever

**SEX**

Spayed Female



**AGE**

6 Years

The information and recommendations provided are based on the images presented by the referring veterinarian. No evaluation can be communicated regarding pathology that was not visible in the image/video clips provided.

Thank you for this referral. If the clinical or image interpretation does not parallel your findings or if I can be of any further assistance please contact me.

**INTERPRETED BY**

Nele Eley (Ondreka),  
DVM Dr. med. vet.,  
DipECVDI

**Nele Eley (Ondreka)**, DVM, Dr. med. vet., DipECVDI  
European Specialist in Veterinary Diagnostic Imaging, Cert. Radiology,  
Senior lecturer University of Giessen/Germany, Veterinary Faculty, Department of Radiology.  
Nele.Eley@sonopath.com

**HOSPITAL NAME**

Animal Paradise  
Hospital

**REFERRING VET**

Dr. Kristen Hellwarth

**INVOICE**

37331

**DATE**

5/3/22