



PATIENT PRESENTING CLINICAL SIGNS

Henry Murphy Intermittent leg lameness
Abnormal PE/Chem/CBC/UA Results: WNL

SPECIES RADIOGRAPHIC STUDY OF THE LEFT FOREARM

Canine Mediolateral view of the left elbow and forearm and craniocaudal view of both forearms, totaling two images available for review.

BREED RADIOGRAPHIC FINDINGS

Golden Retriever The medial coronoid process of the left elbow is reduced in opacity and presents cranial contouring blurring. There is a mild radioulnar step formation as well as extensive sclerosis of the subtrochlear notch of the ulna. Early osseous remodeling of the periarticular margins is seen.

SEX The left shoulder presents within normal limits. No evidence of osteochondritis or osteoarthritis is seen.
Male

RADIOGRAPHIC DIAGNOSIS

AGE • Medial coronoid process pathology of the left elbow with early secondary elbow osteoarthritis.
10 Months

INTERPRETATION OF FINDINGS & FURTHER RECOMMENDATIONS

INTERPRETED BY The radiographic study reveals medial coronoid disease of the left elbow. Mild secondary osteoarthritic changes are seen in this very young dog already. The disease can be bilateral, and further definition by means of CT and arthroscopic revision of the left elbow should be considered in case of persisting lameness.
Nele Eley (Ondreka),
DVM Dr. med. vet.,
DipECVDI

HOSPITAL NAME

New Bridge VP

REFERRING VET

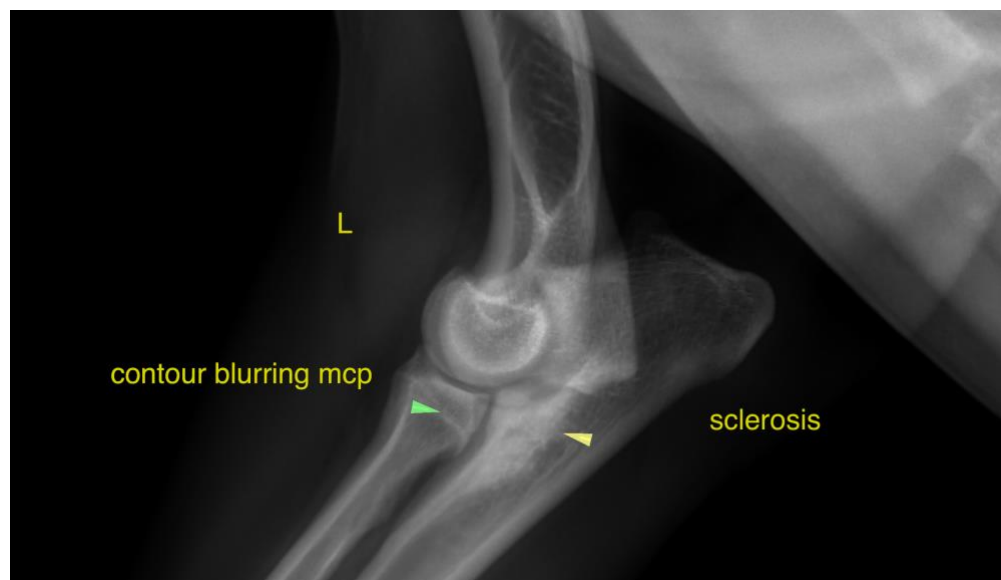
Dr. Abina Glennon

INVOICE

37321

DATE

5/3/22





PATIENT

Henry Murphy

The information and recommendations provided are based on the images presented by the referring veterinarian. No evaluation can be communicated regarding pathology that was not visible in the image/video clips provided.

SPECIES

Canine

Thank you for this referral. If the clinical or image interpretation does not parallel your findings or if I can be of any further assistance please contact me.

BREED

Golden Retriever

Nele Eley (Ondreka), DVM, Dr. med. vet., DipECVDI
European Specialist in Veterinary Diagnostic Imaging, Cert. Radiology,
Senior lecturer University of Giessen/Germany, Veterinary Faculty, Department of Radiology.
Nele.Eley@sonopath.com

SEX

Male

AGE

10 Months

INTERPRETED BY

Nele Eley (Ondreka),
DVM Dr. med. vet.,
DipECVDI

HOSPITAL NAME

New Bridge VP

REFERRING VET

Dr. Abina Glennon

INVOICE

37321

DATE

5/3/22