

**PATIENT**

Mello Wetch

**SPECIES**

Feline

**BREED**

DSH

**SEX**

NM

**AGE**

2 Years

**INTERPRETED BY**Nele Eley, DVM  
Dr. med. Vet. DipECVDI**HOSPITAL NAME**DPC Veterinary  
Hospital**REFERRING VET**

Dr. Rivera

**INVOICE**

52209

**DATE**

5-29-22

**PRESENTING CLINICAL SIGNS**

2YR OLD NEUTERED DSH, 1 OF 2 INDSIDE ONLY BROTHER CATS, PRESENTED FOR HARSH BREATHING(ABDOMINAL EFFORT) AND A COUGH AS IF TRYING TO CLEAR HIS THROAT. PET WAS ADOPTED AS KITTEN AND WAS VACCINATED AND NEUTERED WITH NO OTHER VET VISIT. VOMITS FOOD RIGHT AFTER EATING RANDOMLY  
Abnormal PE/Chem/CBC/UA Results: PE : WNL

**RADIOGRAPHIC STUDY OF THE THORAX**

Right lateral and ventrodorsal views totaling 2 images available for review.

**RADIOGRAPHIC FINDINGS**

The degree of pulmonary inflation is moderate. A moderate generalized bronchial lung pattern is noted and accentuated in the caudodorsal lung field where peribronchial cuffing is seen as well as a mild tree-in-bud appearance of the bronchi.

There is no radiographic evidence of cardiovascular pathology.

Course and width of the trachea are considered within normal limits.

No mediastinal widening is noted.

The thoracic boundaries present within normal limits.

**RADIOGRAPHIC DIAGNOSIS**

- Active chronic bronchial lung pattern.

**INTERPRETATION OF THE FINDINGS & FURTHER RECOMMENDATIONS**

The radiographic findings are highly suggestive for recurrent allergic lower airway syndrome (feline asthma). Infectious bronchitis such as viral, bacterial, parasitic, or protozoal cannot be ruled out as a differential diagnosis. Consider a clinical trial of treatment for feline asthma versus further definition by means of airway endoscopy with airway sampling.



**PATIENT**

Mello Wetch

**SPECIES**

Feline

**BREED**

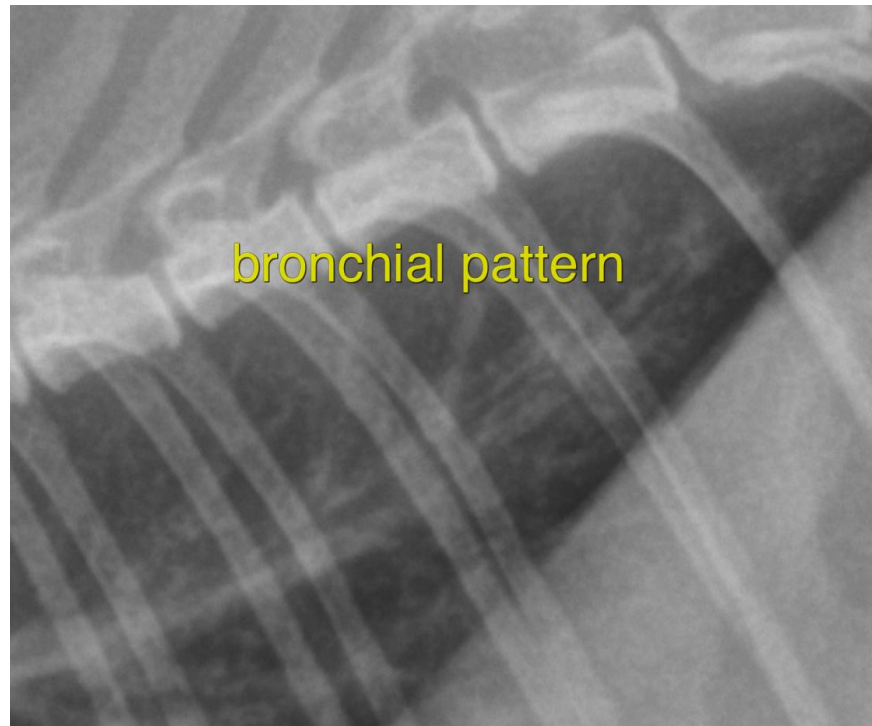
DSH

**SEX**

NM

**AGE**

2 Years



**INTERPRETED BY**

Nele Eley, DVM  
Dr. med. Vet. DipECVDI

**The information and recommendations provided are based on the images presented by the referring veterinarian/sonographer. No evaluation can be communicated regarding pathology that was not visible in the image/video clips provided.**

**HOSPITAL NAME**

DPC Veterinary  
Hospital

Thank you for this referral. If the clinical or image interpretation does not parallel your findings or if I can be of any further assistance please contact me.

**REFERRING VET**

Dr. Rivera

**Nele Eley**, DVM, Dr. med. vet., DipECVDI  
European Specialist in Veterinary Diagnostic Imaging, Cert. Radiology,  
Senior lecturer University of Giessen, Germany, Veterinary Faculty, Department of Radiology  
Nele.Eley@sonopath.com

**INVOICE**

52209

**DATE**

5-29-22