



PATIENT

Via Collins

SPECIES

Canine

BREED

Border Collie

SEX

FS

AGE

4 Years

INTERPRETED BY

Nele Eley, DVM
Dr. med. Vet. DipECVDI

HOSPITAL NAME

Points East West
Veterinary Services

REFERRING VET

David Lane

INVOICE

52177

DATE

5-27-22

PRESENTING CLINICAL SIGNS

See prior U/S report 14210. In addition, please see the attached MRI report. On Jan 28, BMAC/PRP was injected bilaterally into the glenohumeral joint, both SST, the right biceps tendon and left iliopsoas tendon. Patient is asymptomatic clinically, but has yet to return to sprinting activity.

ULTRASONOGRAPHIC STUDY OF THE SHOULDERS & ILIOPSOAS

Findings are compared to prior ultrasound and MRI reports.

ULTRASONOGRAPHIC FINDINGS

Patient has a history of bilateral supraspinatus tendinopathy with biceps impingement and left iliopsoas injury and has received prp injections.

Left Shoulder

6.5mm maximum thickness of the left supraspinatus tendon is seen. There is moderate internal echoarchitectural remodeling and mild ill-defined delineation of the left supraspinatus tendon. Mild biceps impingement is noted. The biceps tendon presents mild swelling and mild effusion. Mild internal echoarchitectural remodeling and small core lesions are seen within the biceps tendon.

Right Shoulder

6.5mm maximum thickness of the right supraspinatus tendon is seen. There is moderate internal echoarchitectural remodeling and mild ill-defined delineation of the right supraspinatus tendon. Mild biceps impingement is noted. The biceps tendon presents mild swelling and mild effusion. Mild internal echoarchitectural remodeling and small core lesions are seen within the biceps tendon.

Right Iliopsoas

The psoas major muscle, musculotendinous junction, and tendon present within normal limits. Mild osseous remodeling of the lesser trochanter at the attachment of the psoas major tendon is noted.

A nonshadowing hyperechoic structure with hypoechoic halo is seen at the superficial and distal margin of the psoas major attachment to the lesser trochanter.

Left Iliopsoas

The visible muscle and musculotendinous junction present within normal limits. Mild echoarchitectural remodeling of the left psoas major tendon as well as moderate osseous remodeling of the lesser trochanter are noted.



PATIENT

Via Collins

ULTRASONOGRAPHIC DIAGNOSIS

- Bilateral supraspinatus tendinopathy with biceps impingement and mild to moderate biceps tenosynovitis with small internal core lesions.
- Bilateral psoas major tendinopathy with prior injury of the left psoas major tendon.

SPECIES

Canine

INTERPRETATION OF THE FINDINGS & FURTHER RECOMMENDATIONS

The ultrasonographic study of the shoulders reveals more or less stationary ultrasonographic changes compatible with bilateral supraspinatus tendinopathy with biceps impingement and chronic biceps tenosynovitis with small core lesions. It is not uncommon that ultrasonographic improvement lags behind the clinical improvement or that the ultrasonographic changes even remain stationary despite clinical improvement. My subjective impression at this point is that the ultrasonographic changes are stationary compared with the prior study.

BREED

Border Collie

SEX

FS

The findings of the left psoas major tendon are compatible with prior / healing injury. No evidence of a new injury of the psoas major tendon is seen. There is mild progression of the osseous remodeling as well as reduced visibility of the echoarchitectural changes within the tendon.

AGE

4 Years

Only minor osseous remodeling of the right psoas major tendon is seen. The hyperechoic structure seen in the distal and superficial aspect of the tendon is unlikely to represent mineralization at least at this point since no shadowing is exhibited by this structure. A fibrotic lesion or small defect within the peritendineum is considered likely; however, this may also be an expression of chronic tendinopathy with remodeling and incompletely mineralized matrix.

INTERPRETED BY

Nele Eley, DVM
Dr. med. Vet. DipECVDI

HOSPITAL NAME

Points East West
Veterinary Services

REFERRING VET

David Lane

INVOICE

52177

DATE

5-27-22



PATIENT

Via Collins

SPECIES

Canine

BREED

Border Collie

SEX

FS

AGE

4 Years

INTERPRETED BY

Nele Eley, DVM
Dr. med. Vet. DipECVDI

HOSPITAL NAME

Points East West
Veterinary Services

REFERRING VET

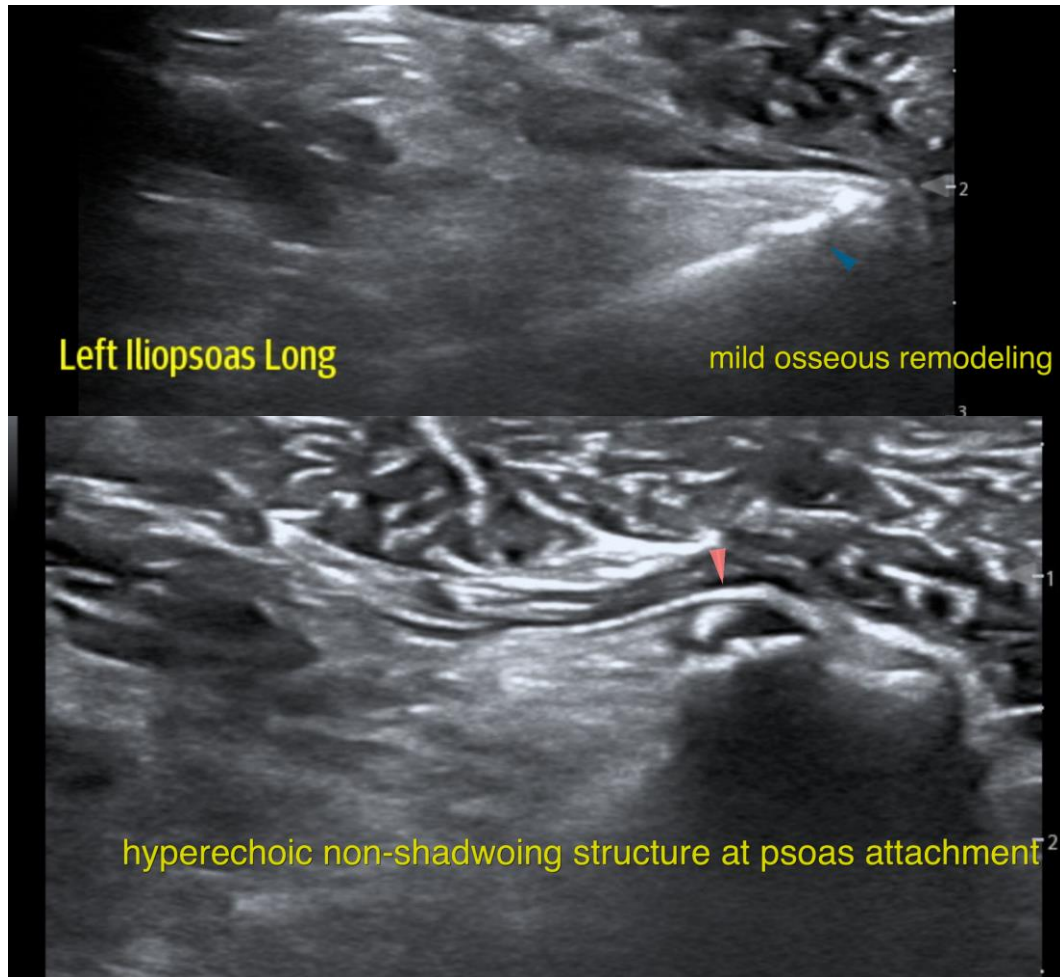
David Lane

INVOICE

52177

DATE

5-27-22





PATIENT

Via Collins

SPECIES

Canine

BREED

Border Collie

SEX

FS

AGE

4 Years

INTERPRETED BY

Nele Eley, DVM
Dr. med. Vet. DipECVDI

HOSPITAL NAME

Points East West
Veterinary Services

REFERRING VET

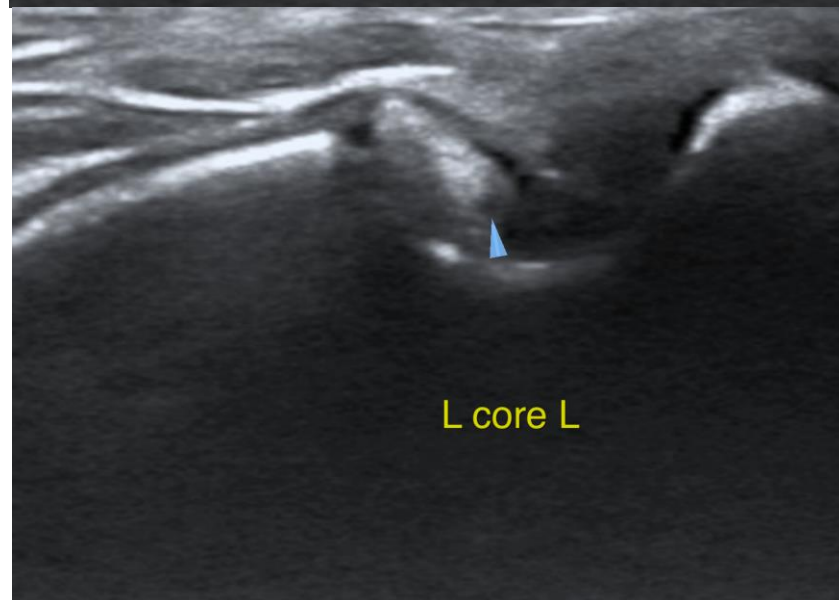
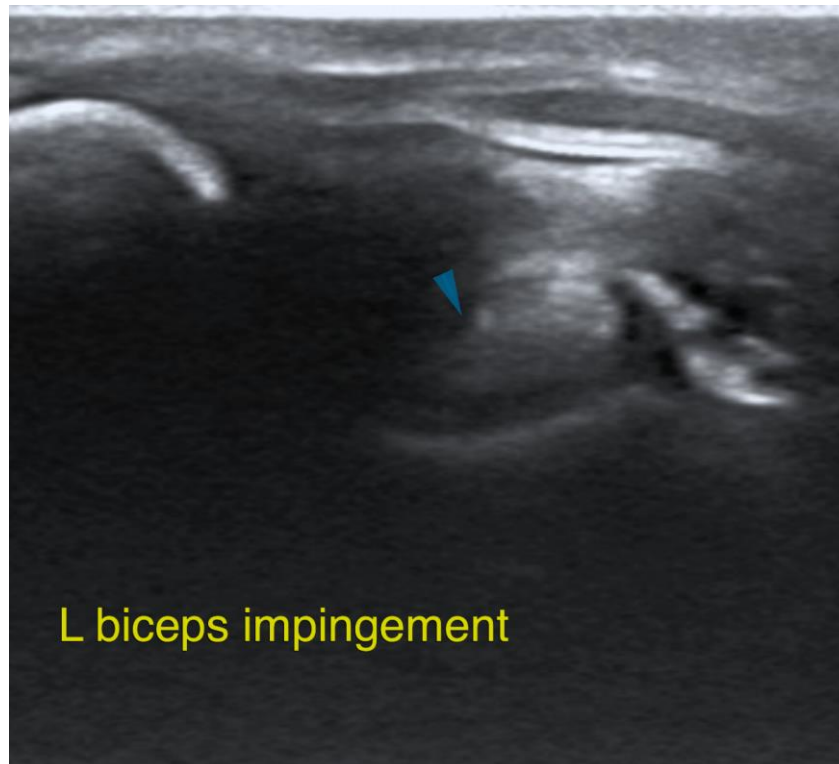
David Lane

INVOICE

52177

DATE

5-27-22





PATIENT

Via Collins

The information and recommendations provided are based on the images presented by the referring veterinarian/sonographer. No evaluation can be communicated regarding pathology that was not visible in the image/video clips provided.

SPECIES

Canine

Thank you for this referral. If the clinical or image interpretation does not parallel your findings or if I can be of any further assistance please contact me.

BREED

Border Collie

Nele Eley, DVM, Dr. med. vet., DipECVDI
European Specialist in Veterinary Diagnostic Imaging, Cert. Radiology,
Senior lecturer University of Giessen, Germany, Veterinary Faculty, Department of Radiology
Nele.Eley@sonopath.com

SEX

FS

AGE

4 Years

INTERPRETED BY

Nele Eley, DVM
Dr. med. Vet. DipECVDI

HOSPITAL NAME

Points East West
Veterinary Services

REFERRING VET

David Lane

INVOICE

52177

DATE

5-27-22