



PATIENT

Dunkin Schneider

PRESENTING CLINICAL SIGNS

Waxing and waning FUO, reluctant to eat, Submandibular LN swelling resolved with antibiotic therapy cytology was supportive of reactive LN, extracted 408 roots, 406, 110 and 209 while under anesthesia for dental cleaning

SPECIES

Canine

COMPUTED TOMOGRAPHIC STUDY OF THE HEAD

Plain and post contrast studies available for review. Tip of the nose not fully included.

BREED

French Bulldog

COMPUTED TOMOGRAPHIC FINDINGS

The conformation of the external auditory meatuses and tympanic bullae is narrow. The nasopharyngeal lumen is narrow. The left tympanic bulla is filled with fluid attenuation contrast negative material. Moderate thinning of the ventrolateral wall of the left tympanic bulla is seen.

SEX

MA

Multiple teeth presents periodontal changes. Partial root resorption and periodontal space widening of the triadans 110, 209, and 406 is seen as well as of the root remnants of the triadan 408.

AGE

8.2 Years

The temporomandibular joints and salivary glands present within normal limits.

The left submandibular lymph nodes are moderately enlarged with heterogeneous contrast enhancement and peripheral fat stranding.

INTERPRETED BY

Nele Eley, DVM
Dr. med. Vet. DipECVDI

The nasal cavities present within the expected limits for a brachycephalic dog.

COMPUTED TOMOGRAPHIC DIAGNOSIS

- Lymphadenopathy with fat stranding of the left submandibular lymph nodes.
- Left sided otitis media.
- Multifocal periodontal disease accentuating the triadans 110, 209, 406, and the root remnants of the triadan 408.

HOSPITAL NAME

Boca Park Animal Hospital

INTERPRETATION OF THE FINDINGS & FURTHER RECOMMENDATIONS

The left sided submandibular lymphadenomegaly is accompanied by peripheral fat stranding which is suggesting lymphadenitis and cellulitis a primary differential diagnosis, however, lymphomatous or other neoplastic infiltrate cannot be ruled out entirely. Correlate with the results of the fine needle aspiration.

REFERRING VET

Laura Warren

The otitis media may be primary secretory due to stenosis of the auditive tube; however, superinfection or primary infectious otitis media cannot be ruled out and further otoscopic workup is recommended.

INVOICE

52228

Dental extractions have been performed already after the CT study.

DATE

5-27-22



PATIENT

Dunkin Schneider

SPECIES

Canine

BREED

French Bulldog

SEX

MA

AGE

8.2 Years

INTERPRETED BY

Nele Eley, DVM
Dr. med. Vet. DipECVDI

HOSPITAL NAME

Boca Park Animal
Hospital

REFERRING VET

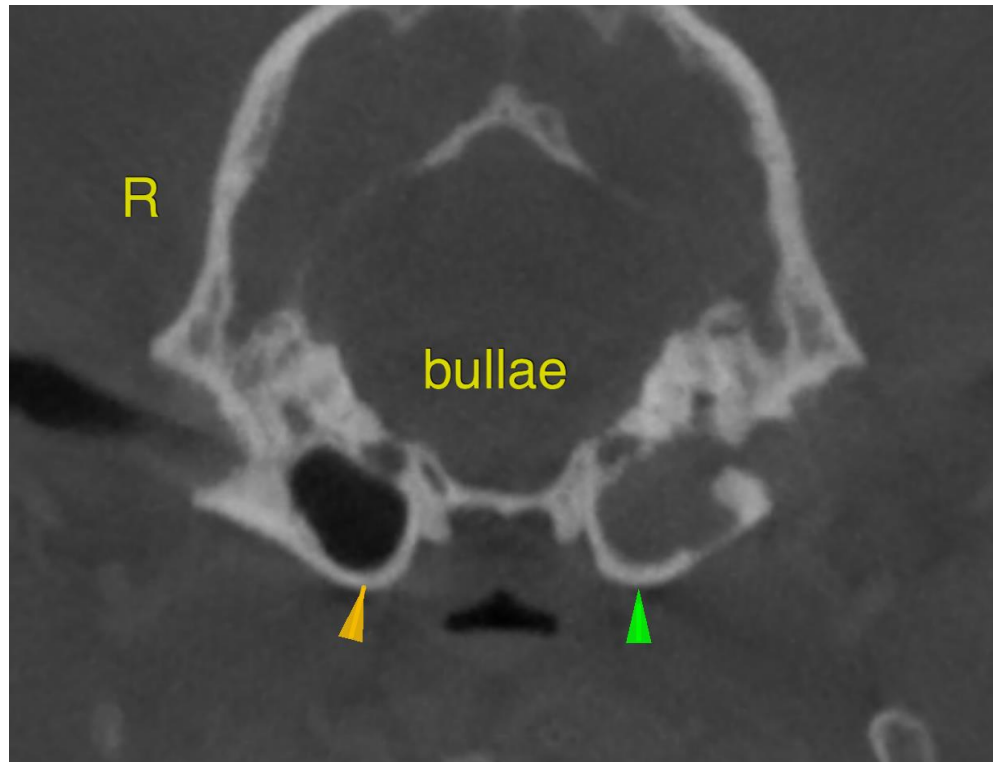
Laura Warren

INVOICE

52228

DATE

5-27-22



The information and recommendations provided are based on the images presented by the referring veterinarian/sonographer. No evaluation can be communicated regarding pathology that was not visible in the image/video clips provided.

Thank you for this referral. If the clinical or image interpretation does not parallel your findings or if I can be of any further assistance please contact me.

Nele Eley, DVM, Dr. med. vet., DipECVDI
European Specialist in Veterinary Diagnostic Imaging, Cert. Radiology,
Senior lecturer University of Giessen, Germany, Veterinary Faculty, Department of Radiology
Nele.Eley@sonopath.com