



PATIENT

Richie Iglina

SPECIES

Canine

BREED

French Bulldog

SEX

Male Neutered

AGE

8Y

WEIGHT

13.2kg

INTERPRETED BY

Nele Eley (Ondreka),
DVM Dr. med. vet.,
DipECVDI

IMAGING PERFORMED BY

BO

HOSPITAL NAME

Green Dog Dental and
Wellness

REFERRING VET

Sherry Vartanian

INVOICE

75116

DATE

5-23-26

PRESENTING CLINICAL SIGNS

No obvious lameness appreciated in clinic, weight bearing on all four limbs evenly. Owner video showed lifting and non-weight bearing on left hind limb

RADIOGRAPHIC STUDY OF THE STIFLES

Mediolateral and craniocaudal views of the right and left stifle totaling 6 images available for review.

RADIOGRAPHIC FINDINGS

Mild periarticular osteophyte formation of the femoral trochlea and patella and minimal articular remodeling are present within the left stifle joint consistent with very mild early degenerative joint disease. No evidence of patella luxation is seen. There is no radiographic evidence of cranial tibial translation to suggest overt cranial cruciate ligament insufficiency. The fabellae are within breed-related normal limits.

The right stifle joint is radiographically unremarkable.

RADIOGRAPHIC DIAGNOSIS

- Very mild degenerative joint changes of the left stifle joint accentuating the femoral patella region. No radiographic evidence of patella luxation or overt cranial cruciate ligament insufficiency.
- Right stifle: radiographically unremarkable.

INTERPRETATION OF FINDINGS & FURTHER RECOMMENDATIONS

The minimal degenerative changes in the left stifle may represent early or chronic low grade joint pathology including mild instability and early degenerative change not yet associated with obvious radiographic instability. However, radiographs are limited in sensitivity for articular pathology such as partial cruciate ligament injury and meniscal disease. Correlation with orthopedic examination findings is recommended. Lameness of other origin including neurologic should be ruled out. Advanced imaging such as MRI could be considered if lameness persists or worsens.



PATIENT

Richie Iglina

SPECIES

Canine

BREED

French Bulldog

SEX

Male Neutered

AGE

8Y

WEIGHT

13.2kg

INTERPRETED BY

Nele Eley (Ondreka),
DVM Dr. med. vet.,
DipECVDI

IMAGING PERFORMED BY

BO

HOSPITAL NAME

Green Dog Dental and
Wellness

REFERRING VET

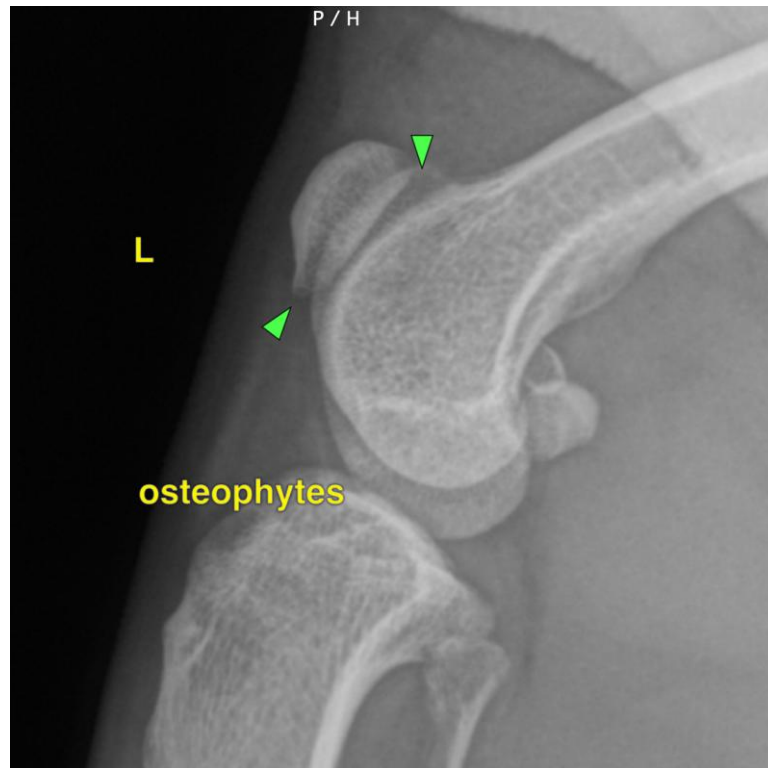
Sherry Vartanian

INVOICE

75116

DATE

5-23-26



The information and recommendations provided are based on the images presented by the referring veterinarian. No evaluation can be communicated regarding pathology that was not visible in the image/video clips provided.

Thank you for this referral. If the clinical or image interpretation does not parallel your findings or if I can be of any further assistance please contact me.

Nele Eley (Ondreka), DVM, Dr. med. vet., DipECVDI
European Specialist in Veterinary Diagnostic Imaging, Cert. Radiology,
Senior lecturer University of Giessen/Germany, Veterinary Faculty, Department of Radiology.
info@sonopath.com