



PATIENT

Max Smith

SPECIES

Canine

BREED

Australian Cattle Dog

SEX

Male

AGE

7

WEIGHT

45.5lbs

INTERPRETED BY

Nele Eley (Ondreka),
DVM Dr. med. vet.,
DipECVDI

IMAGING PERFORMED BY

Jessica Lucas

HOSPITAL NAME

Animal Medical Center
of Corona

REFERRING VET

Carrie Hsing

INVOICE

75114

DATE

5-22-26

PRESENTING CLINICAL SIGNS

Max presents for decreased appetite, lethargy, and drooling with occasional blood seen on tongue. P was seen elsewhere 2 weeks ago for the same symptoms and was prescribed antibiotics and NSAIDs which helped with his signs for about 1 week but symptoms returned after that. Biopsy of tongue was reported to be insignificant. Radiographs were reported normal. Lab work showed mild leukocytosis. P can chew on sticks and a blade of grass was found in this region.
Abnormal PE/Chem/CBC/UA Results: Reported elevated WBC

COMPUTED TOMOGRAPHIC STUDY OF THE HEAD

Plain and post contrast studies are available for review.

COMPUTED TOMOGRAPHIC FINDINGS

There is bilateral irregular soft tissue proliferations centered within the base of the tongue and sublingual region including the expected locations of the sublingual salivary glands although the lesions extend beyond normal glandular margins. The right sided lesion is markedly larger extending into the body of the tongue and measuring approximately 10 cm in length and 3 cm in diameter. The left sided lesion measures approximately 3 x 2 cm and is predominantly confined to the tongue base region. Both lesions show strong contrast enhancement with spongy form appearance and contain multiple small cavitory foci. No mineralized or radiopaque foreign material is identified.

Mild bilateral submandibular and moderate bilateral medial retropharyngeal lymphadenomegaly are present.

No aggressive osseous or dental abnormalities are identified.

The hyoid apparatus is encompassed yet remains intact.

COMPUTED TOMOGRAPHIC DIAGNOSIS

- Bilateral infiltrative and strongly contrast enhancing proliferative soft tissue lesions involving the tongue base/sublingual regions, markedly more extensive on the right.
- Associated mild bilateral submandibular and moderate retropharyngeal lymphadenopathy.
- No CT evidence of radiopaque foreign material or adjacent osseous destruction.

INTERPRETATION OF FINDINGS & FURTHER RECOMMENDATIONS

The imaging appearance is concerning for an inflammatory/infectious infiltrative process vs less likely bilateral neoplasia. Differential diagnosis includes severe pyogranulomatous sialadenitis, cellulitis, atypical abscess formation, foreign body associated chronic inflammatory disease, and less likely infiltrative neoplasia such as salivary gland adenoma, adenocarcinoma, or other soft tissue neoplasia. The bilateral distribution, enhancement pattern, and spongy form/cavitory nature favor an inflammatory/infectious etiology. However, neoplasia cannot be excluded based on CT appearance alone. The previously reported nondiagnostic tongue biopsy may not have sampled representative tissue. Ultrasound or CT guided aspirates/core biopsy from the larger right sided lesion, deeply reaching into the tissue, as well as of the enlarged retropharyngeal lymph nodes, are recommended for definitive diagnosis.



PATIENT

Max Smith

SPECIES

Canine

BREED

Australian Cattle Dog

SEX

Male

AGE

7

WEIGHT

45.5lbs

INTERPRETED BY

Nele Eley (Ondreka),
DVM Dr. med. vet.,
DipECVDD

IMAGING PERFORMED BY

Jessica Lucas

HOSPITAL NAME

Animal Medical Center
of Corona

REFERRING VET

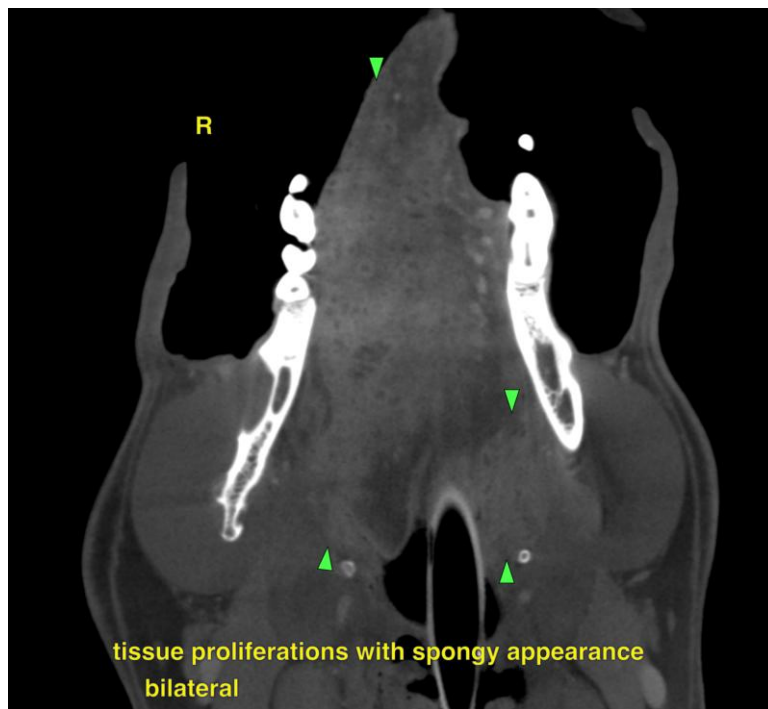
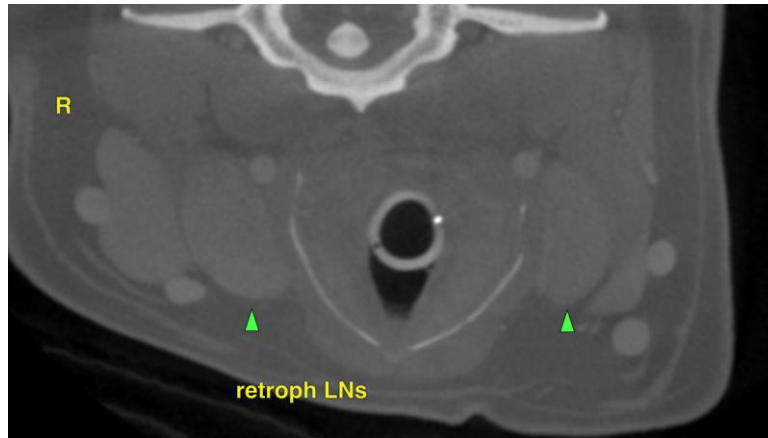
Carrie Hsing

INVOICE

75114

DATE

5-22-26





PATIENT

Max Smith

SPECIES

Canine

BREED

Australian Cattle Dog

SEX

Male

AGE

7

WEIGHT

45.5lbs

INTERPRETED BY

Nele Eley (Ondreka),
DVM Dr. med. vet.,
DipECVDI

IMAGING PERFORMED BY

Jessica Lucas

HOSPITAL NAME

Animal Medical Center
of Corona

REFERRING VET

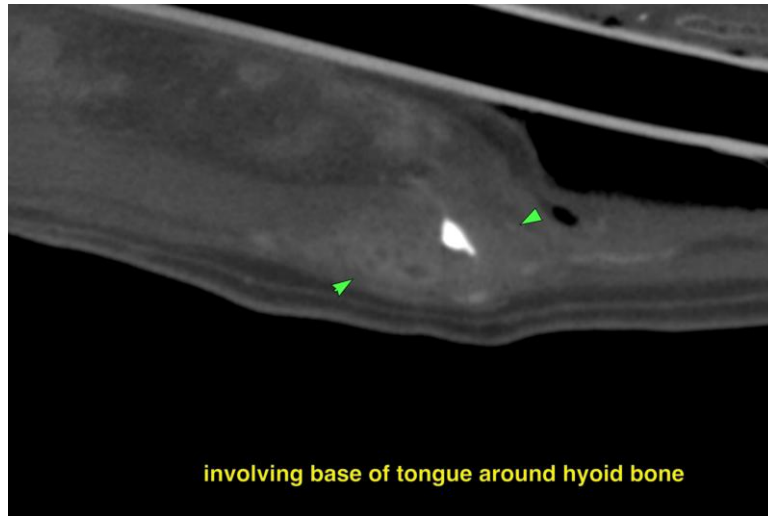
Carrie Hsing

INVOICE

75114

DATE

5-22-26



involving base of tongue around hyoid bone

The information and recommendations provided are based on the images presented by the referring veterinarian. No evaluation can be communicated regarding pathology that was not visible in the image/video clips provided.

Thank you for this referral. If the clinical or image interpretation does not parallel your findings or if I can be of any further assistance please contact me.

Nele Eley (Ondreka), DVM, Dr. med. vet., DipECVDI

European Specialist in Veterinary Diagnostic Imaging, Cert. Radiology,
Senior lecturer University of Giessen/Germany, Veterinary Faculty, Department of Radiology.
info@sonopath.com