



PATIENT

Eve Schick

PRESENTING CLINICAL SIGNS

History of chronic upper respiratory symptoms (sneezing, discharge from left nostril), previously had chronic Mycoplasma. Sneezing stopped after a 1 month course of antibiotics, but has since become an issue again.

SPECIES

Feline

COMPUTED TOMOGRAPHIC STUDY OF THE HEAD

Plain and post contrast studies available for review.

BREED

DSH

COMPUTED TOMOGRAPHIC FINDINGS

Regional turbinate destruction is seen within the left nasal cavity mainly centering the ventral nasal meatus. There also is regional mucosal swelling within the ventral aspect of the left nasal cavity and bilateral nasal choana. The cribriform plate is intact.

SEX

FS

The frontal sinuses and presphenoidal sinuses present within normal limits.

AGE

1 Year

A large amount of fluid attenuating material is seen within the right tympanic bulla. The left tympanic bulla presents within normal limits. The external auditory meatuses present within normal limits.

The bilateral medial retropharyngeal lymph nodes and the left submandibular lymph node present mild symmetric enlargement with increased contrast enhancement.

INTERPRETED BY

Nele Eley, DVM
Dr. med. Vet. DipECVDI

COMPUTED TOMOGRAPHIC DIAGNOSIS

- Regionally destructive rhinitis within the left nasal cavity and rostral nasopharyngitis.
- Right sided otitis media
- Bilateral medial retropharyngeal and left hand sided submandibular lymphadenomegaly.

HOSPITAL NAME

Catskill Veterinary Services, PLLC

INTERPRETATION OF THE FINDINGS & FURTHER RECOMMENDATIONS

The regionally destructive character of the left hand sided rhinitis suggests potential for foreign material related disease. No attenuating foreign material is seen, however, and regional turbinate destruction secondary to infectious rhinitis is another primary differential diagnosis in this case. Viral infection, bacterial infection or mixed infection is considered likely. No specific signs of fungal rhinitis are seen at this point.

REFERRING VET

Dr. Janis McGill

Note the concurrent presence of right hand sided otitis media and consider further otoscopic workup.

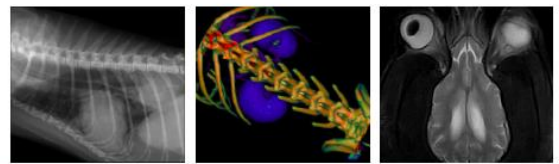
INVOICE

58092

The lymph node changes are compatible with reactive lymphadenitis.

DATE

5-2-23



PATIENT

Eve Schick

SPECIES

Feline

BREED

DSH

SEX

FS

AGE

1 Year

INTERPRETED BY

Nele Eley, DVM
Dr. med. Vet. DipECVDI

HOSPITAL NAME

Catskill Veterinary
Services, PLLC

REFERRING VET

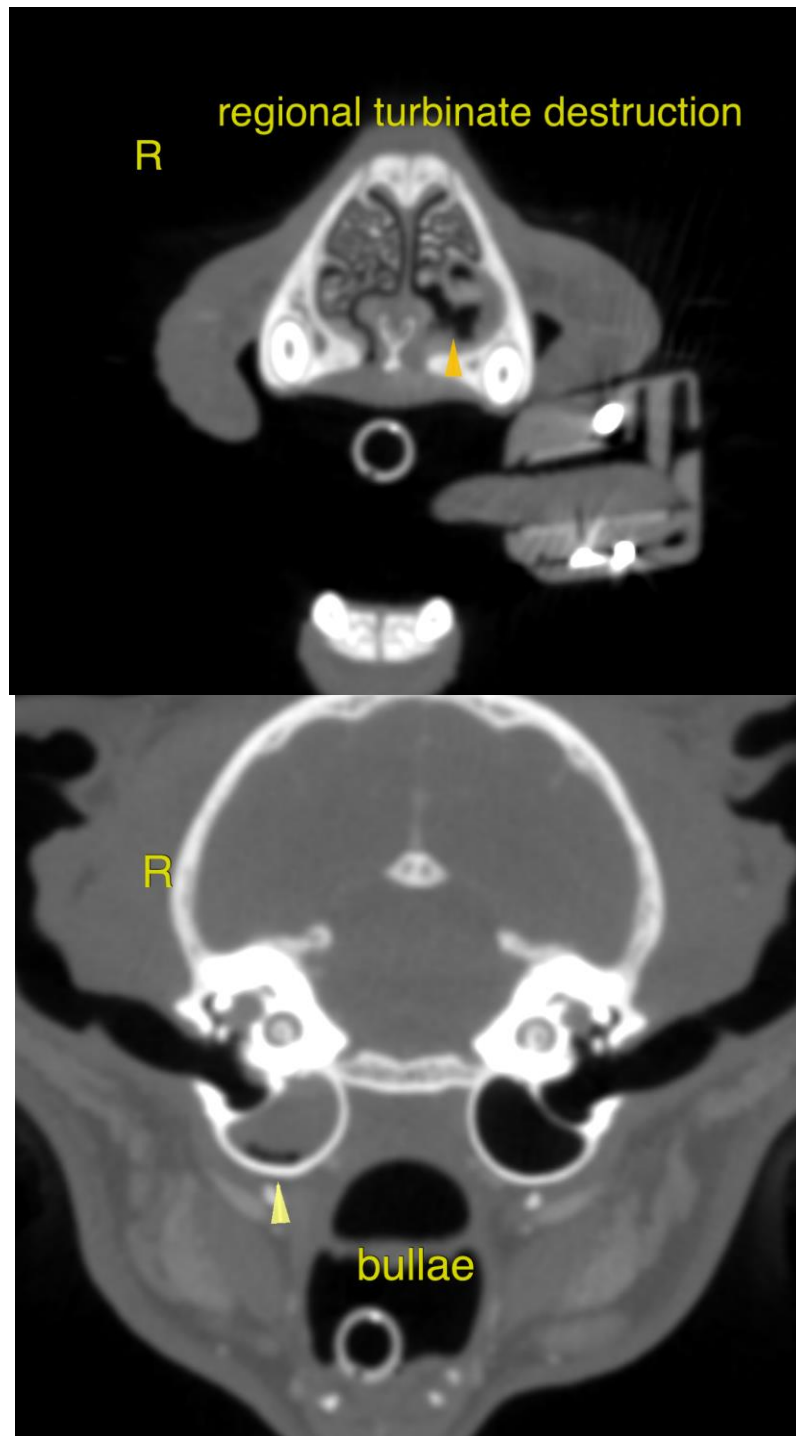
Dr. Janis McGill

INVOICE

58092

DATE

5-2-23





PATIENT

Eve Schick

The information and recommendations provided are based on the images presented by the referring veterinarian/sonographer. No evaluation can be communicated regarding pathology that was not visible in the image/video clips provided.

Thank you for this referral. If the clinical or image interpretation does not parallel your findings or if I can be of any further assistance please contact me.

SPECIES

Feline

Nele Eley, DVM, Dr. med. vet., DipECVDI
European Specialist in Veterinary Diagnostic Imaging, Cert. Radiology,
Senior lecturer University of Giessen, Germany, Veterinary Faculty, Department of Radiology
Nele.Eley@sonopath.com

BREED

DSH

SEX

FS

AGE

1 Year

INTERPRETED BY

Nele Eley, DVM
Dr. med. Vet. DipECVDI

HOSPITAL NAME

Catskill Veterinary
Services, PLLC

REFERRING VET

Dr. Janis McGill

INVOICE

58092

DATE

5-2-23