



PATIENT

Bailey Wood

PRESENTING CLINICAL SIGNS

fluid building SC area (right "armpit). culture positive with two bacteria, antibiotics were helpful. once the meds were done, it was filling back up in a month
Abnormal PE/Chem/CBC/UA Results: please see attached labs

SPECIES

Canine

ULTRASONOGRAPHIC FINDINGS

Right Axillary Region

BREED

G. Retr

The pectoralis muscle and visible brachial plexus structures present within normal limits.

The dermal and subdermal soft tissue layers are thick and irregular with increased echogenicity. No encapsulated fluid accumulation can be seen at this point.

SEX

FS

Thin layers of hypoechoic fluid are seen within the abundant subcutaneous fatty tissue. Hyperechoic foci with multipath reverberation shadowing are seen.

AGE

4 Years

ULTRASONOGRAPHIC DIAGNOSIS

- Regional dermal and subdermal swelling with diffuse fluid accumulation in the right axillary region.

INTERPRETATION OF THE FINDINGS & FURTHER RECOMMENDATIONS

The ultrasonographic findings support the presence of regional cellulitis in the right axillary region. No evidence of foreign material or encapsulation is seen at this point. There appears to be mild emphysema within the affected tissue which can be due to infection with gas forming bacteria or secondary to drainage or probing of the region.

The brachial plexus vessels and nerves are not involved. The pectoralis muscle presents within normal limits.

INTERPRETED BY

Nele Eley, DVM
Dr. med. Vet. DipECVDI

HOSPITAL NAME

Downtown AH

REFERRING VET

AHN

INVOICE

58105

DATE

5-2-23



PATIENT

Bailey Wood

SPECIES

Canine

BREED

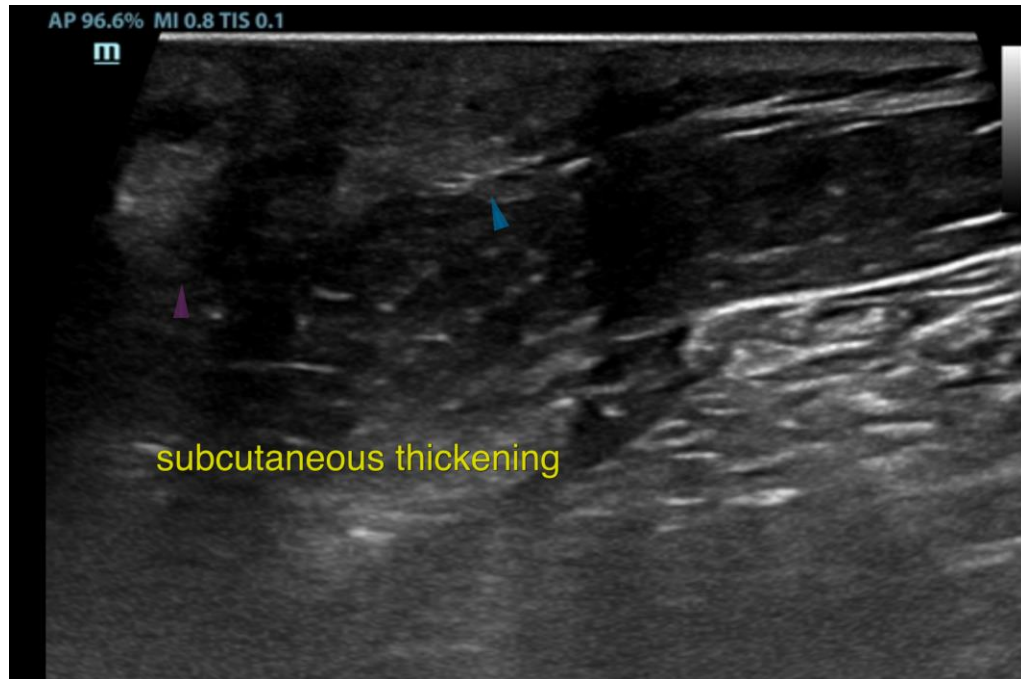
G. Retr

SEX

FS

AGE

4 Years



INTERPRETED BY

Nele Eley, DVM
Dr. med. Vet. DipECVDI

The information and recommendations provided are based on the images presented by the referring veterinarian/sonographer. No evaluation can be communicated regarding pathology that was not visible in the image/video clips provided.

Thank you for this referral. If the clinical or image interpretation does not parallel your findings or if I can be of any further assistance please contact me.

HOSPITAL NAME

Downtown AH

Nele Eley, DVM, Dr. med. vet., DipECVDI
European Specialist in Veterinary Diagnostic Imaging, Cert. Radiology,
Senior lecturer University of Giessen, Germany, Veterinary Faculty, Department of Radiology
Nele.Eley@sonopath.com

REFERRING VET

AHN

INVOICE

58105

DATE

5-2-23