



PATIENT PRESENTING CLINICAL SIGNS

Rylee Reinoehl
Lame right rear since February, right rear quadriceps atrophy, bunny hops bilaterally after short leash walks (recently restarted) Carprofen, Gabapentin

SPECIES ULTRASONOGRAPHIC FINDINGS

Canine **Right Stifle Musculature**

BREED

Mix

Regional swelling with loss of the muscle fiber echoarchitecture, decreased echogenicity, and increased heterogeneity is noted at the origin of the right lateral gastrocnemius muscle circumferential to the lateral fabella. The fabella appears to be mildly displaced distally and caudally. The osseous contour of the fabella is irregular with convex protrusions and a moderate amount of irregular new bone formation.

SEX

FS

The medial right gastrocnemius presents within normal limits. The surrounding musculature presents within normal limits other than mild generalized increase in echogenicity which may support the presence of atrophy.

Left Stifle Musculature

AGE

10 Months

The left stifle musculature was scanned for comparison and presents within normal limits.

ULTRASONOGRAPHIC DIAGNOSIS

- Subacute to chronic proximal right lateral gastrocnemius injury with osteopathy and hyperostosis of the lateral fabella.

INTERPRETED BY

Nele Eley, DVM
Dr. med. Vet. DipECVDI

INTERPRETATION OF THE FINDINGS & FURTHER RECOMMENDATIONS

HOSPITAL NAME

Rylee Reinoehl

The ultrasonographic findings suggest presence of right lateral gastrocnemius musculotendinopathy at the origin of the muscle level with the lateral fabella and caudodistal femur. Consider single traumatic event with partial avulsion versus chronic repetitive microinjury as potential underlying causes with the latter being considered slightly less likely based on the ultrasonographic findings and patient demographics.

REFERRING VET

Sands

INVOICE

51856

DATE

5-2-22



PATIENT

Rylee Reinoehl

SPECIES

Canine

BREED

Mix

SEX

FS

AGE

10 Months

INTERPRETED BY

Nele Eley, DVM
Dr. med. Vet. DipECVDI

HOSPITAL NAME

Rylee Reinoehl

REFERRING VET

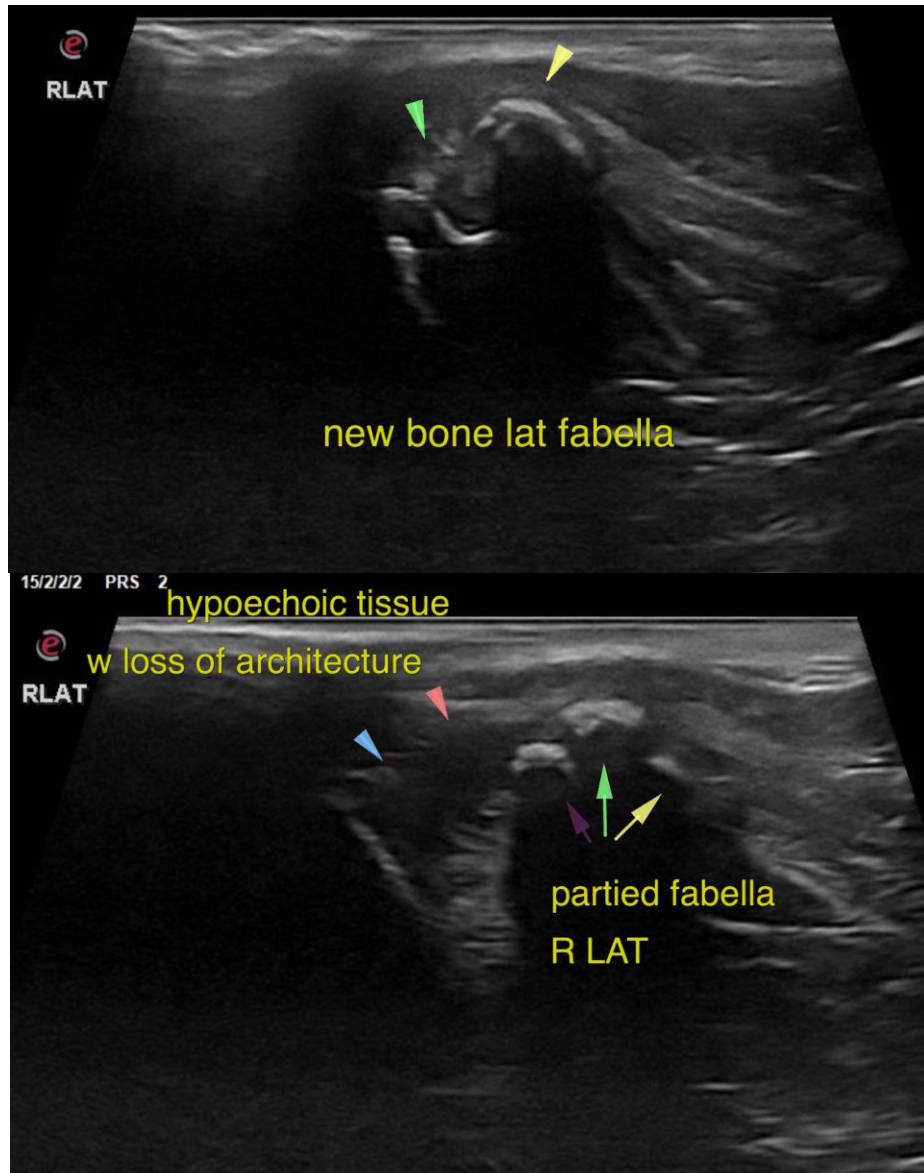
Sands

INVOICE

51856

DATE

5-2-22





PATIENT

Rylee Reinoehl

SPECIES

Canine

BREED

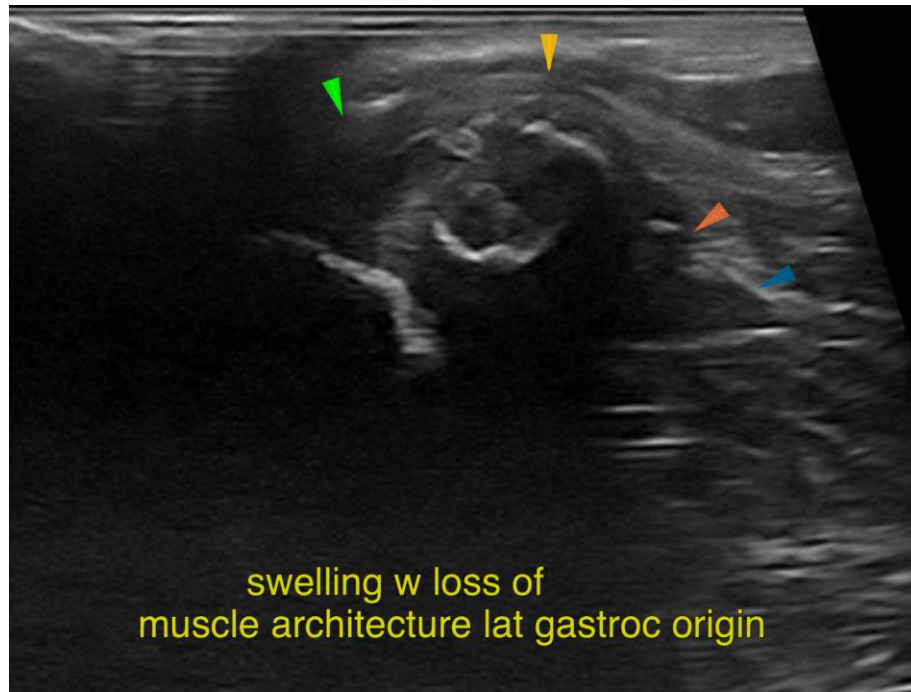
Mix

SEX

FS

AGE

10 Months



INTERPRETED BY

Nele Eley, DVM
Dr. med. Vet. DipECVDI

The information and recommendations provided are based on the images presented by the referring veterinarian/sonographer. No evaluation can be communicated regarding pathology that was not visible in the image/video clips provided.

Thank you for this referral. If the clinical or image interpretation does not parallel your findings or if I can be of any further assistance please contact me.

HOSPITAL NAME

Rylee Reinoehl

Nele Eley, DVM, Dr. med. vet., DipECVDI
European Specialist in Veterinary Diagnostic Imaging, Cert. Radiology,
Senior lecturer University of Giessen, Germany, Veterinary Faculty, Department of Radiology
Nele.Eley@sonopath.com

REFERRING VET

Sands

INVOICE

51856

DATE

5-2-22